©TEAM OF AUTHORS, 2023

B.G. Guliev[1,2], A.E. Talyshinsky[2], M.U. Agagyulov[1], A.A. Andrianov[1]

SAFETY AND EFFICIENCY OF RETROGRADE INTRARENAL SURGERY WITHOUT X-RAY GUIDANCE

[1]Department of urology (Head – prof. B.K. Komyakov) of North-Western State Medical University named after I.I. Mechnikov, Saint Petersburg, Russia; [2]Center of Urology with robot-assisted surgery of City Mariinsky hospital (Chief – prof. A.A. Zavrajnov), Saint Petersburg, Russia

Corresponding author: B.G. Guliev – Ph.D., MD, professor, Head of Center of Urology with robot-assisted surgery of City Mariinsky hospital; e-mail: gulievbg@mail.ru

Introduction. The main stages of flexible ureteroscopy in patients with renal stones are usually performed under X-ray guidance. Long-term exposure of ionizing radiation can have negative effects on the patients with nephrolithiasis and the operating team.

Aim. To study the results of retrograde intrarenal surgery (RIRS) without fluoroscopic guidance.

Materials and methods. The results of flexible ureteroscopy (fURS) without X-ray-guidance in 76 patients were analyzed. There were 46 (53.3%) men and 30 (46.7%) women. The average age was 50.4±14.6 years. All patients underwent laboratory tests and non-contrast-enhanced computed tomography to determine the size and density of the stone. In all cases, preoperative ureteral stenting was performed. The average stone size was 10.5±4.2 mm. First, ureteroscopy with a rigid endoscope was done to assess the ureter and determine the depth of the introducing ureteral access sheath. After removing the ureteroscope along the guidewire, a ureteral access sheath was put at this distance. An inspection of the collecting system and laser fragmentation of kidney stones were performed using a flexible ureteroscope. In 64 (84.2%) patients, a 4.7 Ch stent was put at the end of the procedure, while in the remaining 12 (15.8%) patients, a ureteral catheter was left for 1–2 days. The operation time, stone-free rate, and the number of intra- and postoperative complications were studied.

Results. All fURS were successful and performed without X-ray guidance. The average operation time was 42.5±8.0 minutes. After the first session, stone-free rate was 92.1% (70/76). In 6 (7.9%) cases, residual stones were found, which were completely removed after the second session. Intraoperative complications, namely perforation of the upper calyx by the distal end of the ureteral access sheath, were observed in 2 (2.6%) patients, which did not require any additional interventions. Postoperative complications occurred in 10 (13.2%) patients, including fever in 6 (7.9%) and hematuria in 4 (5.3%) cases. There were no serious complications, such as ureteral perforation or sepsis, and no blood transfusion was performed.

Conclusion. Flexible ureteroscopy with laser lithotripsy can be performed safely and effectively without X-ray guidance.

K e y w o r d s: *urolithiasis, nephrolithiasis, kidney stones, intracorporeal lithotripsy, flexible ureteroscopy, laser lithotripsy, RIRS, lithotripsy without X-ray control*

Authors declare that there is no conflict of interest. For citation: Guliev B.G., Talyshinsky A.E., Agagyulov M.U., Andrianov A.A. Safety and efficiency of retrograde intrarenal surgery without X-ray guidance. Urologiia. 2023;6:38-43.

Doi: https://dx.doi.org/10.18565/urology.2023.6.38-43

Introduction. Currently, flexible ureteroscopy (URS) is actively used in the treatment of kidney stones [1–3]. The widespread development is undoubtedly associated with the active introduction of flexible endoscopes and laser lithotripters. This method has become more popular among urologists due to its less invasiveness compared to percutaneous nephrolithotomy. According to the guidelines of the European Association of Urology, flexible ureteroscopy is an alternative to extracorporeal shockwave lithotripsy and a first-line treatment for small renal stones (<10 and 10–20 mm) and a second-line treatment for renal stones >20 mm [4]. X-ray control is used at various stages of the procedure, including insertion of a guidewire and ureteral access sheath (UAS), inspection of the collecting system, clarification of the stone location or the presence of residual fragments, and putting a ureteral stent. The use of fluoroscopy in urological interventions is associated with risks such as inducing malignancies as a result of radiation exposure to the patient and surgical team [5–7]. According to the International Commission on Radiological Protection, radiation exposure received during the diagnosis stage, treatment and follow-up is cumulative, which is especially important, considering high risk of stone recurrence [5]. This concern has led specialists to search for ways not only to reduce, but also to eliminate radiation exposure during endourological procedures [8]. Therefore, publications began to appear in the literature on the results of X-ray-free endoscopic interventions for ureteral stones [9–15]. The first studies were dedicated to the results of X-ray-free URS for ureteral stones [9–12, 14, 15].

Subsequently, publications appeared on the possibility of performing retrograde intrarenal surgery (RIRS) without fluoroscopy, but the number of such works is



Fig. 1. Ureteroscopy with a rigid endoscope before using flexible ureteroscope for lithotripsy. The distance from the external opening of the urethra to the renal pelvis is determined

limited [13, 16–20]. The aim of our study was to evaluate the safety and efficiency of X-ray-free RIRS in the treatment of small kidney stones.

Materials and methods. This study included the results of X-ray-free URS in 76 patients who were treated at the Center of Urology with Robot-Assisted Surgery of the Mariinsky Hospital. There were 46 (53.3%) men and 30 (46.7%) women. The average age of the patients was 50.4±14.6 (from 28 to 70) years. Patients with renal anomalies, bilateral ureteral and kidney stones, and past urinary tract procedures were excluded from the study. All patients underwent laboratory tests and non-contrast computed tomography to determine the stone size and density, and preoperative ureteral stenting was performed in all cases. The average stone size was 10.5±4.2 mm. The characteristics of patients undergoing X-ray-free URS are shown in the *Table*.

All interventions were planned as flexible URS. The procedure was performed under general anesthesia in the lithotomy position by an experienced urologist, who previously performed more than 250 cases. Immediately prior to RIRS, preoperative antibiotic therapy with a third-generation cephalosporin was usually administered. The fluoroscopic C-arm was always in the operating room for use if necessary. Initially, diagnostic URS was performed using a 9.5 Ch rigid ureteroscope to exclude any pathological changes in the ureter (stone, stricture or deviation) that could cause difficulties during placement of UAS. It also allows optical dilatation of the ureter, which can help with insertion of the UAS. URS was performed using a 0.038-inch hydrophilic guidewire with a flexible tip. The endoscope was passed to the collecting system, and the flexible part of the guidewire was insert into the pelvis under visual control. After localizing the distal end of the endoscope in the pelvis for correct and safe insertion of the UAS, the distance was determined by marking on the outer part of the ureteroscope (*Fig. 1*). After insertion of the guidewire, the ureteroscope was removed, again for aligning it with UAS in order to the establish the depth of insertion (*Fig. 2*). Next, a rigid ureteroscope was passed parallel to the guidewire into the bladder to visually control the adequate passage of the UAS along the guidewire for a set distance

Table

Data of patients with kidney stones, who underwent RIRS without fluoroscopy

Studied indicators Abs..		Number of patients	
		%	
Number of patients		76	100.0
Gender	Male	46	53.3
	Women	30	46.7
Age of patients, years		50.4±14.6 (28–70)	
Body mass index, kg/m^2		25.4±7.2 (24.2–36.5)	
Stone size, mm		10.5±4.2	
The side of the stone	Left	42	55.3
	Right	34	44.7
Baseline symptoms	Ipsilateral pain	36	47.4
	Hematuria	14	18.4
Number of stones	Single	68	89.5
	Multiple	8	10.5
Localization of stones	Pelvis	36	47.4
	Middle calyx	10	13.2
	Lower calyx	22	29.0
	Pelvis + lower calyx	8	10.4
Recurrent stones	No	60	79.0
	Yes	16	21.0
Past procedures	PCNL	10	13.2
	ESWL	6	7.9
Pre-stenting		76	100.0

Note. PCNL – percutaneous nephrolithotomy, ESWL – extracorporeal shock-wave lithotripsy.



Fig. 2. The rigid ureteroscope and the ureteral access sheath are compared to determine the depth of its advancement

until resistance develop or any deviation was observed. Typically, the UAS was placed at a predetermined distance to avoid perforation of the collecting system (*Fig. 3*). During deep placement, isolated cases of perforation of the upper calyx were observed, but they did not require additional measures (*Fig. 4*). For flexible URS, a disposable endoscope Lithovue (Boston Scientific) was used, which was passed through the ureteral access sheath to the collecting system. Initially, an inspection was performed in order to evaluate the anatomical features and to localize the stone. When a stone was found in the lower calyx, a Dormia basket was used to relocate it to the upper calyx or pelvis for more convenient fragmentation. In all patients, an Auriga 200 holmium laser with 230 μm laser fiber were used for lithotripsy. When crushing the stone, a high-frequency and low-power mode (10–15 Hz) was chosen (0.8–1.0 J). At the end of the procedure, a final inspection of the collecting system was performed to identify residual stones. Next, UAS was removed, and URS was done using a rigid endoscope to exclude any damage to the ureter. In 64 (84.2%) of 76 patients, the procedure was completed with the insertion of a stent 4.7 Fr with a length of 24 or 26 cm. The localization of the upper end of the stent was determined visually and using renal ultrasound, while the position of distal end was assessed using ureteroscope. The stent was usually removed after 2–3 weeks. In 12 (15.8%) patients, a ureteral catheter was put for 1–2 days.

Duration of the procedure and its efficiency, the number of intra- and postoperative complications were studied. Surgical time was measured from the time of cystoscopy with stent removal to drainage of the upper urinary tract. Postoperative complications were classified according to Clavien–Dindo. The efficiency of RIRS was assessed using plain urography for radiopaque and non-contrast computed tomography for radiolucent stones before discharge from the hospital. The procedure was considered effective in the absence of residual stones or their presence ⩽3 mm in size.

Results. All procedures were successful and performed without X-ray control. In all cases, it was possible to place UAS and perform lithotripsy. The operation time ranged from 35 to 80 minutes (average of 42.5±8.0). First-session RIRS was effective in 70 (92.1%) of 76 patients. In remaining 6 (7.9%) patients, residual stones were identified, which were completely removed during the second session. Intraoperative complications, including perforation of the upper calyx by the distal end of the UAS were observed in 2 (2.6%) patients. However, they did not require any additional interventions. Postoperative complications occurred in 10 (13.2%) cases, among them



Fig. 3. The ureteral access sheath is introduced to a predetermined distance

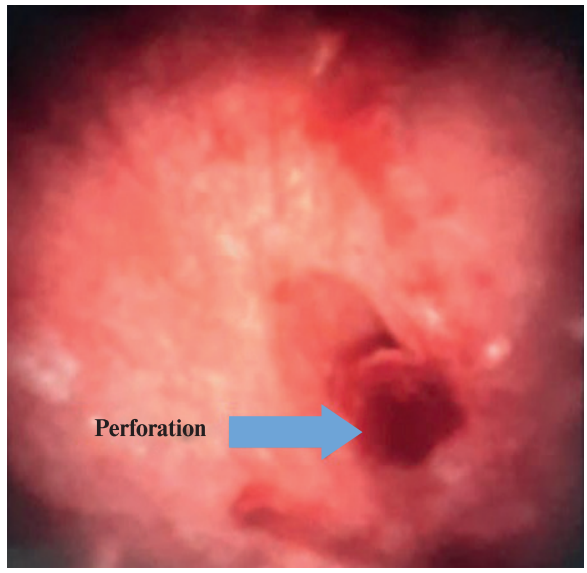

Fig. 4. Perforation of the upper calyx during deep advancement of the ureteral access sheath

fever in 6 (7.9%) and hematuria in 4 (5.3%) patients. There were no serious complications, such as ureteral perforation or sepsis, and no blood transfusion was performed.

Discussion. RIRS is an effective and reliable method for patients with kidney stones with a high success rate. Use of fluoroscopy is one of its disadvantages, as well as for other endourological procedures performed for urolithiasis. Medical radiation poses a potential risk of carcinogenesis in both patients and surgical team. Particularly, malignant neoplasms of the thyroid gland, skin, and hematological diseases can develop [21, 22]. The main criterion of radiation exposure is fluoroscopy time. According to a study of R.S. Hsi et al. [10], for standard URS it was 144 s, while G.O. Hellawell et al. [23] reported a mean time of about 78 (6-414) s. Further, M.E. Lipkin et al. [24] found that in 30 nonobese men

who underwent URS, the mean fluoroscopy time was 47 s and the radiation dose was 0.31-7.17 mSv.

According to their data, one pulse per second roughly corresponds to a radiation dose of 0.01–0.02 mSv, which is equal to that obtained with chest X-ray (0.02 mSv) [25]. As a result, the dose of ionizing radiation is the same as for one chest film multiplied by the number of fluoroscopy pulses during URS. Therefore, the patient and medical personnel are exposed to a higher dose of ionized radiation, the reduction of which is important for the safety of the procedure.

The first study of X-ray-free URS was performed in patients with distal ureteral stones [9]. The authors reported the need for fluoroscopy in 4% of cases, with no complications. In another publication in which half of the patients had proximal and mid-ureteral stones, fluoroscopy was required in 7.52% and minor complications were observed in 11% of cases [26].

In a retrospective comparative study that included 100 patients with ureteral and renal stones, G. Olgin et al. [11] described the technique of X-ray-free URS in 50 cases. In this study, URS was performed using a stepwise technique, and the results were similar in two groups. The authors reported that X-ray-free URS is feasible and effective for the treatment of kidney and ureteral stones.

In recent years, there have been published the results of X-ray-free RIRS [13, 16-20]. H.I. Cimen et al. [17] performed X-ray-free procedures in 93 patients. In all cases, URS with a rigid endoscope was initially performed, with subsequent insertion of UAS along the guidewire under visual control. Next, flexible URS with laser lithotripsy was done. Prestented patients were excluded from the study. The mean stone size was 14.7±5 (7–32) mm and 42 (45.1%) patients had inferior calyx stones. In another work, S. Senel et al. [18] studied 350 patients who underwent RIRS for renal and upper ureteral stones. This retrospective study compared RIRS with and without fluoroscopy. There were 255 patients in the X-ray-free group. The authors found that there was no difference in stone-free status and complications between two groups (86.3 vs. 87.0%, 17.9 vs. 15.7%, respectively). The authors concluded that X-ray-free RIRS is a feasible and safe method. M. Kiras et al. [19] performed flexible URS in 576 patients without the use of fluoroscopy, which was successful in 96.7% (557/576), and the remaining 19 cases required fluoroscopy for various reasons. The average stone size was 11.6±5.2 mm, and the procedure time was 39.4±8.2 min. The efficiency of first-session RIRS was 83.3%. The second and third sessions were performed in 32 (5.7%) and 7 (1.2%) cases, respectively. Overall, the complication rate was 11.8% and all of them were minor (Clavien–Dindo grade I or II). We performed X-ray-free RIRS in 76 patients with renal stones to avoid X-ray radiation dose. The efficiency of the first procedure was 91.6%, and the number of postoperative complications was minimal.

The data from various authors and our results show that X-ray-free RIRS is technically possible and most justified in simple cases. However, the possible serious complications should be kept in mind, especially for inexperienced endourologists. Insertion of UAS is accompanied by risks of damage to upper urinary tract at any level, which undoubtedly limits the enthusiasm for completely eliminating X-ray guidance during RIRS. This conclusion is one of the main recommendations of the International Stone Disease Alliance from 2023 and should be followed until evidence of the efficiency of alternative techniques with a high degree of reliability becomes available [27]. In our work, we analyzed the results of X-ray-free URS in the treatment of patients without renal anomalies and with a small solitary kidney stone, as well as without previous procedures on the upper urinary tract, which indicates the limited possibility of using the results obtained in the entire population of patients with urolithiasis.

It should also be mentioned that radiation exposure depends not only on intraoperative fluoroscopy, but also on imaging methods performed preoperatively. A low-dose CT scan provides a "safe exposure window" for intraoperative fluoroscopy, ensuring that the total radiation dose remains within acceptable limits. In all cases included in our work, non-contrast CT was performed in a standard mode, with an average radiation dose of 10 mSv. In order to further limit radiation exposure, in such cases we suggested X-ray-free URS.

However, we do not encourage young and inexperienced urologists to perform RIRS without fluoroscopy, which can cause serious complications. With the gaining of sufficient experience in a selected group of patients with solitary kidney stones, it is possible to safely done URS without fluoroscopy. For these purposes, we also recommend actively using 3D models of the collecting system, which allow to plan the procedure and practice its stages. In addition, these interventions are performed in the endourological operating room, where there is a constant presence of a C-arm, which can always be used if necessary.

In addition to the advantages of X-ray-free URS, the limitations of the study should be pointed out. First of all, our work is a retrospective analysis of patient data, which does not exclude the influence of other parameters. Secondly, the study does not have a control group, therefore the precise comparison with the standard technique is not possible. As a consequence, further prospective randomized studies are needed to compare the results of RIRS with and without fluoroscopy.

Conclusion. Analysis of literature and our data show that URS without fluoroscopy is effective and safe method for kidney stones in patients without renal anomalies and previous procedures. In addition, X-ray-free URS may be useful in certain clinical situations, such as urolithiasis in pregnant women, and is more convenient for surgeons since heavy lead aprons are not required. However, one should be aware of the associated risks and perform X-ray-free URS only if the surgeon has sufficient experience.

REFERENCES

1. *Zeng G., Zhao Z., Mazzon G., Pearle M., Choong S., Skolarikos A. et al.* European Association of Urology section of urolithiasis and international Alliance of urolothiasis joint consensus on retrograde intrarenal surgery for the management of renal stones. Eur Urol Focus. 2022;8 (5):1461–1468. Doi: 10.1016/j.euf.2021.10.011.
2. *Popov S.V., Orlov I.N., Sytnik D.A., Radzhabov R.M.* Retrograde intrarenal surgery for kidney stones larger than two centimetres. Urology Herald. 2022;10(3):98–105. (In Russ.) https://doi.org/10.21886/2308-6424-2022-10-3-98-105. Russian (Попов С.В., Орлов И.Н., Сытник Д.А., Раджабов Р.М. Ретроградная интраренальная хирургия при камнях почек более двух сантиметров. Вестник урологии. 2022;10(3):98–105. Doi: 10.21886/2308-6424-2022-10-3-98-105).

3. *Guliyev B.G., Komyakov B.K., Agagyulov M.U., Yagubov Kh.Kh., Korol E.I., Talyshinsky A.E.* Retrograde intrarenal surgery for kidney diseases. Urologiia. 2022;5:84–89. Doi: 10.18565/urology.2022.5.84-89. Russian (Гулиев Б.Г., Комяков Б.К., Агагюлов М.У., Ягубов Х.Х., Король Е.И., Талышинский А.Э. Ретроградная интраренальная хирургия заболеваний почек. Урология. 2022;5:84–89. Doi: 10.18565/urology.2022.5.84-89).
4. *Türk C., Petřík A., Sarica K., Seitz C., Skolarikos A. et al.* EAU guidelines on interventional treatment for urolithiasis. Eur Urol. 2016;69(3):475–482. Doi: 10.1016/j.eururo.2015.07.041.
5. *Cardis E., Vrijheid M., Blettner M., Gilbert E., Hakama M., Hill C. et al.* The 15-country collaborative study of cancer risk among radiation workers in the nuclear industry: estimates of radiation-related cancer risks. Radiat Res. 2007;167:396–416. Doi: 10.1667/RR0553.1.
6. *Violette P.D., Szymanski K.M., Anidjar M., Andonian S.* Factors determining fluoroscopy time during ureteroscopy. J Endourol. 2011;25(12):1837–1840. Doi: 10.1089/end.2011.0204.
7. *Hein S., Wilhelm K., Miernik A., Schoenthaler M., Suarez-Ibarrola R. et al.* Radiation exposure during retrograde intrarenal surgery (RIRS): a prospective multicenter evaluation. World J Urol. 2021;39(1):217–224. Doi: 10.1007/s00345-020-03160-9.
8. *Bhanot R., Hameed Z., Shah M., Juliebo-Jones P. et al.* ALARA in urology: steps to minimise radiation exposure during all parts of the endourological journey. Curr Urol. Rep. 2022; 23 (10):256–259. Doi: 10.1007/s11934-022-01102-z.
9. *Mandhani A., Chaudhury H., Gupta N., Singh H.K., Kapoor R., Kumar A.* Is fluoroscopy essential for retrieval of lower ureteric stones? Urol Int. 2007;78(1):70–72. Doi: 10.1159/000096938.
10. *Hsi R.S., Harper J.D.* Fluoroless ureteroscopy: zero-dose fluoroscopy during ureteroscopic treatment of urinary-tract calculi. J Endourol. 2013;27:432–437. Doi: 10.1089/end.2012.0478.
11. *Olgin G., Smith D., Alsyouf M., Arenas J.L., Engebretsen S. et al.* Ureteroscopy without fluoroscopy: a feasibility study and comparison with conventional ureteroscopy. J Endourol. 2015; 29(6):625–629. Doi: 10.1089/end.2014.0237.
12. *Danilovic A., Nunes E., Lipkin M.E., Ferreira T., Torricelli F.C. et al.* Low dose fluoroscopy during ureteroscopy does not compromise surgical outcomes. J Endourol. 2019;33(7):527–532. Doi: 10.1089/end.2018.0722.
13. *Manzo B.O., Lozada E., Manzo G., Sánchez H.M., Gomez F. et al.* Radiation-free flexible ureteroscopy for kidney stone treatment. Arab J Urol. 2019;17(3):200–205. Doi: 10.1080/2090598X.2019.1606381.
14. *Clark K., King S., Patel A., Hill S., Deem S., Hale N.E.* Reducing radiation exposure to patients and staff during routine ureteroscopic stone surgery: adopting a fluoroless technique. Cureus. 2021;13(7):e16279. Doi: 10.7759/cureus.16279.
15. *Guliyev B.G., Komyakov B.K., Talyshinsky A.E., Povago I.A., Allakhverdi-yev O.N.* Non-trentgen ureterolithotripsy with ureteral stones. Experiment. and a wedge. urology. 2022;16(4):85–90. Doi: 10.29188/2222-8543-2022-16-4-85-90. Russian (Гулиев Б.Г., Комяков Б.К., Талышинский А.Э., Поваго И.А., Аллахвердиев О.Н. Безрентгеновская уретеролитотрипсия при камнях мочеточника. Эксперим. и клин. урология. 2022;16(4):85–90. Doi: 10.29188/2222-8543-2022-16-4-85-90).
16. *Kirac M., Tepeler A., Guneri C., Kalkan S., Kardas S. et al.* Reduced radiation fluoroscopy protocol during retrograde intrarenal surgery for the treatment of kidney stones. Urol J. 2014;11:1589–1594.
17. *Çimen H.İ., Halis F., Sağlam H.S., Gökçe A.* Flouroscopy-free technique is safe and feasible in retrograde intrarenal surgery for renal stones. Turk J Urol. 2017;43(3):309–312. Doi: 10.5152/tud.2017.24638.
18. *Senel C., Tuncel A., Balcı M. et al.* Safety and reliability of fluoroscopy-free technique in retrograde intrarenal surgery. Minerva Urol Nefrol. 2018;70:606–611. Doi: 10.23736/S0393-2249.18.03228-9.
19. *Kirac M., Kopru B., Ergin G., Kibar Y., Biri H.* Is fluoroscopy necessary during flexible ureteroscopy for the treatment for the treatment of renal stones? Arab J Urol. 2020;18(2):112–112. Doi: 10.1080/2090598X.2019.1702242.
20. *Birowo P., Raharja P.A., Atmoko W., Rasyid N.* X-ray-free endoscopic combined intrarenal surgery for complex proximal ureteral stone: a case report. Res Rep Urol. 2021;13:121–125. Doi: 10.2147/RRU.S299707.
21. *Krupp N., Bowman R., Tenggardjaja C., Jellison F., Hill B. et al.* Fluoroscopic organ and tissue-specific radiation exposure by sex and body mass index during ureteroscopy. J Endourol. 2010;24:1067–1072. Doi: 10.1089/end.2020.0040.
22. *Thaker A., Navadeh S., Gonzales H., Malekinejad 'M.* Effectiveness of policies on reducing exposure to ionizing radiation from medical imaging: a systematic review. J Am Coll Radiol. 2015;12:1434–1445. Doi: 10.1016/j.jacr.2015.06.033.
23. *Hellawell G.O., Mutch S.J., Thevendran G., Well E., Morgan R.J.* Radiation exposure and the urologist: what are the risks? J Urol. 2005;173:948–952. Doi: 10.1096/01.ju.0000170232.58930.8f.
24. *Lipkin M.E., Wang A.J., Toncheva G., Ferrandino M.N., Yoshisumi T.T., Preminger G.M.* Determination of patient radiation dose during ureteroscopic treatment of urolithiasis using validated model. J Urol. 2012;187:920–924. Doi: 10.1016/j.juro.2011.10.159.
25. *Mettler F.A., Huda W., Yoshizumi T.T., Mahesh M.* Effective doses in radiology and diagnostic nuclear medicine: A catalog. Radiology. 2008;248:254–263. Doi: 10.1148/radiol.2481071451.
26. *Tepeler A., Armagan A., Akman T., Silay M.S., Akcay M., Basibuyuk I. et al.* Is fluoroscopic imaging mandatory for endoscopic treatment of ureteral stones? Urology 2012;80:1002–1006. Doi: 10.1016/j.urology.2012.02.082.
27. *Zeng G., Traxer O., Zhong W., Osther P., Pearle M.S., Preminger G.M. et al.* International Alliance of Urolithiasis guideline on retrograde intrarenal surgery. BJU Int. 2023;131:153–164. Doi: 10.1111/bju.15836.

Received 30.12.2022
Accepted 16.06.2023
Financing source: absents.

Author information:

Guliev B.G. – Ph.D., MD, professor, Head of Center of Urology with robot-assisted surgery of City Mariinsky hospital, Saint Petersburg, Russia; e-mail: gulievbg@mail.ru; ORCID iD 0000-0002-2359-6973

Talyshinsky A.E. – urologist at the Center of Urology with robot-assisted surgery of City Mariinsky hospital, Saint Petersburg, Russia; e-mail: ali-ma@mail.ru. ORCID 0000-0002-3521-8937

Agagyulov M.U. – Ph.D. student at the Department of Urology of FGBOU VO North-Western State Medical University named after I.I. Mechnikov, Saint Petersburg, Russia; e-mail: Murad1311@bk.ru ORCID: 0000-0001-9647-9690

Andrianov A.A. – resident at the Department of Urology of FGBOU VO North-Western State Medical University named after I.I. Mechnikov, Saint Petersburg, Russia; e-mail: mr.haisenberg001@gmail.com. ORCID iD: 0000-0001-6905-0581