CLINICAL CASE

©TEAM OF AUTHORS, 2024
УДК 616.66-001

N.M. Keulimzhayev, U. Zhanbyrbekuly, Ye.Zh. Mukhambetov

CLINICAL CASE OF PENILE FRACTURE

Department of Urology and Andrology, Astana Medical University, Astana, Republic of Kazakhstan

Corresponding author: Ye.Zh. Mukhambetov – 7th course, residency at the Astana Medical University, Astana, Republic of Kazakhstan; e-mail: erkebulan.muhambet@gmail.com

A clinical case of a penile fracture as a result of an unsuccessful sexual intercourse, which later required surgical treatment in the form of corporoplasty with opening and draining of the hematoma, is discussed in the article. Penile fracture is a rare urological emergency that requires immediate medical attention to avoid long-term complications, including penile curvature and erectile dysfunction.

K e y w o r d s: *penile fracture, sexual trauma, hematoma, surgical intervention, erectile dysfunction, penile curvature*

The authors declare no conflict of interest. For citation: Keulimzhayev N.M., Zhanbyrbekuly U., Mukhambetov Ye.Zh. Clinical case of penile fracture. Urologiia. 2024;1:96-99.
Doi: https: //dx.doi.org/10.18565/urology.2024.1.96-99

Penile fracture is a urological emergency characterized by unilateral or bilateral rupture of the tunica albuginea and cavernous bodies of the penis. This is a rare condition that predominantly occurs as a result of traumatic flexion of the erect penis, mainly during sexual (intercourse and masturbation) and non-sexual activity (penile manipulation, rolling over in bed injury, the practice "tagaandan", blunt trauma), and less commonly due to injury, for example, from a direct blow with a hard object.

Penile fractures are usually accompanied by severe pain and a cracking sound, immediate loss of erection, curvature, swelling, and hematoma. During erection, the cavernous bodies are tightly filled with blood, and the thickness of the tunica albuginea of the cavernous bodies decreases from 2 to 0.25 mm, which leads to easy rupture with minor physical impact.

In most cases, the diagnosis is made clinically, but in equivocal cases, imaging tests (e.g., ultrasound [US], magnetic resonance imaging [MRI]) may be required. Retrograde urethrography is recommended in all patients with confirmed penile fracture to exclude concomitant urethral injury.

Complications can be very diverse, including secondary infection, abscess formation, urethral rupture, penile deformation, which prevents sexual activity, and/or erectile dysfunction of varying severity, from mild to complete absence.

The problem of penile fracture and its consequences is a rather rare, which explains the small number of studies in the Russian literature. Certain questions were reflected in the foreign publications. There is a fairly extensive description of identical clinical cases, some points of which should be discussed in more detail.

According to modern data, the vast majority of penile fractures occur during sexual intercourse. In a study by R. Barros et al. 288 observations of penile fracture were reviewed, of which in 88.5% the main etiological factor was sexual trauma [1]. According to another study, this figure was slightly lower and amounted to 76.5% (69/90) [2] (Table 1).

After analyzing the information from these studies, we can conclude that the most highly traumatic position is the "doggy style", and the least traumatic is the "woman on top". Penile injury occurs in adult men, with an average age of 38–39 years. Accordingly, in order to avoid penile fracture, it is recommended to use positions with the lowest risk of injury.

J. Ory and G. Bailly independently studied the mechanism of injury. The erect penis comes out of the vagina and does not go back in properly, buckling as the pelvis moves forward, resulting in injury [3].

Non-sexual causes of penile trauma include masturbation, rolling over in bed injury with spontaneous nocturnal erections, and the Middle Eastern practice "tagaandan", which is forceful bending of the erect penis to achieve detumescence. The most common symptoms, the so-called triad, are presented in Table 2.

Urethral rupture is a rare condition, mostly associated with high-energy trauma. There are 14 cases described in the literature, where 11 were with partial and 3 with complete rupture of the urethra [10]. In the study of R. Barros et al. urethral rupture was observed in 18.7% of cases, of which 13.5% of patients had a partial rupture, and 5.2% had a complete rupture. Authors observed the following relationship: high-energy trauma leads to bilateral damage to the cavernous bodies, which in turn is complicated by complete rupture of the urethra.

Our clinical case, which will be presented below, is characterized by a unilateral fracture of the corpus cavernosum, which corresponds to the vast majority of similar observations, occurring in 69% of patients, while a bilateral fracture is seen in 31%.

Table 1

The most common causes of penile fracture according to the literature [1, 2]

Study	R. Barros et al., 2020 [1]	R. Barros et al., 2017 [2]
Total number of cases	288	90
Average age, years	38.2 (18–66)	39 (18–66)
	Etiology (%)	
Sexual intercourse, positions:	255 (88.5)	69(76.8)
- "doggy style"	110 (43.1)	37 (53.6)
- "man on top"	103 (40.3)	23 (33.3)
- "woman on top"	31(12.1)	9 (13.1)
- other	11 (4.3)	–
Masturbation	9 (3.1)	–
Penile manipulation	18 (6.3)	16 (17.7)
Rolling over in bed injury	1 (0.3)	3 (3.3)
No data on the mechanism of injury	5 (1.7)	–
Blunt trauma	–	2 (2.2)

R. Barros et al. believe that the typical manifestations do not require additional examinations. The diagnosis is established clinically. However, in doubtful cases, additional examination methods such as US and MRI must be used to confirm the diagnosis [6].

J. Ory and G. Bailly indicate that 36 hours after penile injury, MRI is the preferred image method. One cannot but agree with this approach, since MRI shows a higher quality of visualization [3]. Retrograde urethrography is performed when urethral injury is suspected [1], although some studies indicate that it may produce false-negative results in 28.5% of cases [7]. Most authors agree that in case of a penile fracture, it is necessary to perform emergent surgical treatment [1–5], which is demonstrated in our observation.

J. Ory and G. Bailly emphasize, that if the clinical manifestations indicate penile fracture, then surgical intervention should be immediate. A delay may be only in case of a questionable diagnosis, but provided that additional examination can be carried out quickly. Early surgery (within 24 hours) resulted in a complication rate of only 7.6% compared with 68.7% for later surgery (within 24 hours to 4 days) [3]. Therefore, the British Association of Urological Surgeons recommends to perform repair within the first 24 hours.

Recurrent fracture is extremely rare. In the foreign literature, only 7 cases are described in which patients received re-injury with an interval of 90 days to 9 years, and only in 2 cases, the cause of repeat fracture was sexual activity [8].

In a study by R. Barros et al., postoperative complications, sexual and urinary function were assessed. Among the complications, 9 (14.7%) patients had erectile dysfunction, and in 8 (13.1%) penile curvature was developed [1]. Zargooshi, assessing long-term complications in 352 patients, found only 8 people with complaints of premature ejaculation, erectile dysfunction, decreased libido, and family conflicts [9]. El Atat et al. described 300 cases and recorded complications in 40 (13.3%) patients, of whom 14 (23.3%) developed penile curvature and 2 (0.6%) had erectile dysfunction.

A description of a clinical case

A 50-year-old patient had a trauma during sexual intercourse. The first aid was provided by himself, including application of ice and a tight bandage, after that he arrived at the emergency room at "City Hospital No. 1". After examination he was hospitalized in the uroandrology department.

History of trauma: the injury was received during sexual intercourse with his wife in the "woman on top" position. They did not notice any blood in the urine. Upon admission of the patient to a hospital, there were complaints of acute pain in the groin area. A "cracking sound" was noticed. The penis had a dark purple color.

Medical history: hypothyroidism, chronic cholecystitis and pancreatitis. Patient had an allergic reaction to wormwood, manifesting by hives. Bad habits included smoking, frequent drinking of alcohol (at least 1-2 times a week, about 300-500 ml of a 40-degree drink over the past 15 years). He had hemorrhoidectomy 11 years ago. No pathological changes were observed in other organs and systems.

Examination and palpation: the external genitalia were developed according to age. Status localis: the penis was

Table 2

The most common symptoms of penile fracture [1, 2]

Symptoms	Number of examined patients	Proportion of symptoms in the total number of cases, %
Hematoma	288	100.0
Penile detumescence	238	82.6
"Cracking sound"	220	76.3
"Eggplant deformity"	200	69.4
Acute pain	191	66.3
Urethral bleeding	37	12.8
Acute urinary retention	1	0.3

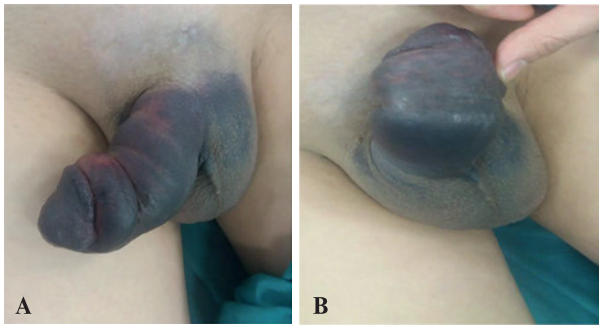

Fig. 1. Features of fracture before surgery
A – lateral view; B – frontal view.

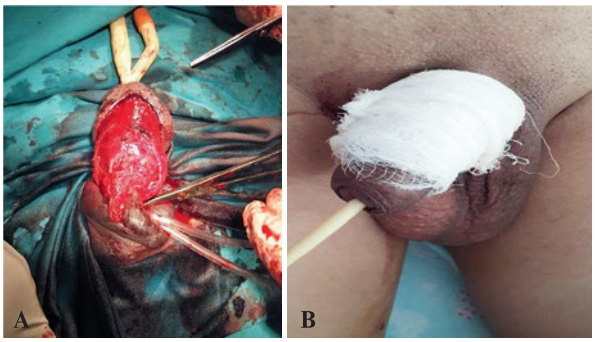

Fig. 2. Surgical reconstruction
A – intraoperative view; B – dressing after reconstruction

swollen, had a dark purple color, the deviation to the left from the central axis by 45 degrees was visually determined. On the right, at the level of the lower third of the penile shaft, a hematoma was observed in a form of swollen area 6x5 cm of dark bluish color. The scrotum was swollen, painful on palpation, the testicles were unremarkable and difficult to palpate (Fig. 1: A, B).

Laboratory tests, including complete blood count blood, urinalysis, biochemical profile and coagulation test were within normative values. On US, rupture of the tunica albuginea with unilateral damage of the right corpus cavernosum was found, however, urethral trauma was excluded.

A clinical diagnosis of penile fracture without urethral rupture was made.

Management: emergency hospitalization (according to the guidelines of the British Association of Urological Surgeons, which recommend repair within the first 24 hours).

Surgical treatment was performed under spinal anesthesia. A corporoplasty with opening and draining of the penile hematoma was done. After positioning the patient, the surgical field was painted three times with alcohol. Under spinal anesthesia, a circular (subcoronal) incision was made in the skin of the penis 1 cm downward from the coronary sulcus, after which it was retracted to the base of the penis. There was a 6x5 cm hematoma in the lower third of the right cavernous body. The Buck's fascia of the penis was dissected in this area, exposing the tunica albuginea. A total of 40 ml of blood with clots were evacuated. Further, a cavity was rinsed with a 3% solution of hydrogen peroxide. Upon further inspection, an area of 0.5–0.6 cm rupture of the tunica albuginea and the corpus cavernosum on the right was found. The edges of the wound were sutured with vicryl. Hemostasis was checked (Fig. 2A). Buck's fascia and the superficial fascia of the penis were sutured with vicryl. The penile skin was returned towards the glans. The skin was sutured with interrupted sutures. A compressive bandage was applied (Fig. 2B).

The Foley catheter was removed after 3 days. Further, urination was painful, but without difficulties. In the postoperative period, Bruzepami 10 mg IM was prescribed to prevent erection. Next dress changing was done after 7 days. Ketorol was prescribed for 3 days. Antibacterial therapy included ceftriaxone 1 g BID for 7 days. Strict restriction of sexual activity was recommended for 1 month. After 3 months the International Index of Erectile Function-5 score was 26 points (no erectile dysfunction). No postoperative complications were observed (Fig. 3).



Fig. 3. Penis after surgical treatment
A – after 2 months, B – after 3 months.

Currently, surgical management of patients with penile fracture is the most relevant, which is confirmed by the described clinical case. The AUA (American Urology Association) also recommends surgical treatment to preserve penile function. Diagnosis should be based on MRI or US.

The EAU (European Association of Urology) guidelines are somewhat different from the AUA. The EAU suggests urinalysis in all patients with genital trauma, and any amount of micro- or gross hematuria should be an indication for retrograde urethrography. Among the diagnostic methods, most urologists often perform cystoscopy and additionally US. MRI or cavernosography can be done only if the diagnosis cannot be established clinically.

The EAU guidelines also emphasize that simple penile hematomas that are not associated with severe detumescence are usually easily diagnosed and can be treated with nonsteroidal anti-inflammatory drugs and ice.

According to the EAU guidelines, early intervention (<24 hours from injury) resulted in a complication rate of 7.6% compared with 68.7% with later procedure, and the rate of erectile dysfunction was only 1.3%. Conversely, conservative management is associated with erectile dysfunction in 62% cases [13].

Penile fracture is an acute urological emergency and requires immediate surgical treatment to avoid long-term complications, including penile curvature and erectile dysfunction. In our opinion, to prevent long-term complications, it is necessary to perform emergency intervention.

According to most studies, the diagnosis of penile fracture can only be made based on the typical clinical manifestations. However, we believe that US or MRI allows to confirm the diagnosis, localize the site of rupture of the tunica albuginea and exclude the damage to the urethra.

The etiology of penile fracture is mainly due to sexual activity and, to a lesser extent, other causes. Repeated fracture rarely occurs. The most "dangerous" positions are "doggy style", "woman on top", "man on top". The more high-energy the injury, the more severe bilateral cavernous damage develops. Timely hospitalization and surgical intervention within the first 24 hours is associated with a low level of postoperative complications, allowing men to return to a full sexual activity.

Regardless of the type of penile injury, surgical treatment has the same goals:

- restoration of the anatomical structure,
- prevention of erectile dysfunction and penile curvature;
- maintaining the penile length and normal urination.

REFERENCES

1. *Barros R., Hampl D.* Lessons learned after 20 years' experience with penile fracture. International Brazilian Journal of Urology. 2020;46(3):409–416.
2. *Barros R., Schulze L.* Relationship between sexual position and severity of penile fracture. International journal of impotence research. 2017;5:207–209.
3. *Ory J., Bailly G.* Management of penile fracture. Canadian Urological Association journal. 2019;13(6S4):72–74.
4. *Garofalo M., Bianchi L.* Sex-related penile fracture with complete urethral rupture: A case report and review of the literature. Archives of Italian Urology and Andrology. 2015;87(3):260–261.
5. *Gulmi F.A.* Penile Fracture. Review Urology. 2018;20(1):41–42.
6. *Koifman L., Barros R., Jenior R.A., Cavalcanti A.G., Favorito L.A.* Penile fracture: diagnosis, treatment and outcomes of 150 patients. Urology. 2010;76:1488–1492.
7. *Mydlo J., Hayyeri M., Macchia R.J.* Urethrography and cavernosography imaging in a small series of penile fractures: a comparison with surgical findings. Urology. 1998;51:616–619.
8. *Ridyard D.G., Phillips E.A., Munarriz R.* Recurrent Penile Fracture: A Case Report and Review of Literature. Journal Integrative Medicine in Nephrology and Andrology. 2010;2:132–134.
9. *Zargooshi J.* Sexual function and tunica albuginea wound healing following penile fracture: An 18-year follow-up study of 352 patients from Kermanshah, Iran. Journal of Sexual Medicine. 2009;6:1141–1150.
10. *El-Assmy A., El-Tholoth H., Mohsen T., Ibrahiem el H.* Long-term outcome of surgical treatment of penile fracture complicated by urethral rupture. Journal of Sexual Medicine. 2010;7:3784–3788.
11. *Ridyard D., Phillips E., Munarriz R.* Recurrent Penile Fracture: A Case Report and Review of Literature. Journal of Integrative Nephrology and Andrology. 2015;2(4):132–134.
12. *El Atat R., Sfaxi M., Benslama M., Amine D., Ayed M., Mouelli S., et al.* Fracture of the penis: management and long-term results of surgical treatment. Experience in 300 cases. The Journal of Trauma. 2008;64(1):121–125.
13. EAU Guidelines. Edn. presented at the EAU Annual Congress Milan, 2021. ISBN 978-94-92671-13-4.
14. AUA Guideline. American Urological Association (AUA); May 2020.
15. *Haas C.A., et al.* Penile fracture and testicular rupture. World journal of urology. 1999;17(2):101–106.

Received 11.02.2023
Accepted 17.10.2023
Financing source: Absents

Author information:

Keulimzhayev N.M. – assistant of the Department of Urology and Andrology, Astana Medical University, Astana, Republic of Kazakhstan. https://orcid.org/0000-0003-1143-1650

Zhanbyrbekuly U. – Ph.D., associate professor, Head of the Department of Urology and Andrology, Astana Medical University, Astana, Republic of Kazakhstan. https://orcid.org/0000-0003-1849-6924

Mukhambetov Ye.Zh. – 7th course, residency at the Astana Medical University, Astana, Republic of Kazakhstan; e-mail: erkebulan.muhambet@gmail.com. https://orcid.org/0000-0003-0653-476X