©TEAM OF AUTHORS, 2024

O.B. Loran[1,3], Guspanov R.I.[2,4], S.V. Kotov[2,4], A.V. Seregin[1,3], A.D. Morozov[3], D.A. Bogdanov[2,4]

RECONSTRUCTIVE PROCEDURES IN WOMEN WITH IRRADIATION INJURIES OF URINARY TRACT: CHANGE OF A PARADIGM

[1]Russian Medical Academy of Continuous Professional Education (RMACPE), Department of Urology and Surgical Andrology, Moscow, Russia [2]FGAOU VO Pirogov Russian National Research University, Moscow, Russia
[3]S.P. Botkin's State Clinical Hospital, Moscow, Russia 4GBUZ MMKC "Kommunarka", Moscow, Russia

Corresponding author: R.I. Guspanov – Ph.D., associate professor at the Department of Urology and Andrology of Pirogov Russian National Research Medical University, Moscow, Russia; e-mail: renat@guspanov.ru

Introduction. Radiation therapy is one of the main methods of treating pelvic malignant tumors, which provides good oncological results. Specific features of the pelvic anatomy may result in various radiation injuries of adjacent organs, which are complicated by genitourinary fistulas, post-radiation fibrosis with the formation of hydronephrosis, microcyst, reducing the quality of life.
Aim. To describe the relevance and importance of the correct choice of surgical treatment in patients with post-radiation urinary tract injuries.
Materials and methods. The group of irradiation injuries of the urinary tract included 60 patients aged 39–65 years. 19 (31.7%) women with various post-radiation ureteral injurie, who underwent reconstructive surgery using isolated bowel segments, were included in the study group.
Results. Substitution of the ureter by intestinal segment in patients with extensive post-radiation ureteral strictures provides good functional results. During follow-up computed tomography, an absence of urinary tract obstruction was confirmed in 16 (84.2%) patients, while in 3 (15.8%) cases an obstruction was diagnosed, followed by nephrectomy due to loss of function in 1 woman (5.3%). When assessing renal function using the dynamic nuclear scintigraphy, improvement in function was revealed in 14 (73.7%) patients, stabilization in 2 (10.5%), deterioration in 3 (15.8%). Histological examination revealed that inflammatory infiltration and the absence of a clear margins of the stricture area were more pronounced in patients who had had internal ureteral stent prior to reconstruction. A number of clinical cases demonstrating the treatment tactics of this group of patients is presented in the article.
Conclusion. Based on the extensive experience of two centers and long follow-up, we suggest scientifically proven approach to surgical treatment of radiation injuries of the urinary tract, the implementation of which will significantly improve medical and social rehabilitation.

K e y w o r d s: radiation therapy, complications, ureteral stricture, substitution by the bowel segment

The authors declare that they have no conflicts of interest. For citation: Loran O.B., Guspanov R.I., Kotov S.V., Seregin A.V., Morozov A.D., Bogdanov D.A. Reconstructive procedures in women with irradiation injuries of urinary tract: change of a paradigm. Urologiia. 2024;2:11-17.
Doi: https: //dx.doi.org/10.18565/urology.2024.2.11-17

Introduction. Currently, pelvic cancers account for up to 35% of newly diagnosed malignant neoplasms in men (prostate gland, bladder, colon) and 18% in women (bladder, cervix and body of the uterus, colon) [1].

Radiation therapy (RT) is the main method of treating pelvic tumors, which provides good oncological results. It is generally recognized that the therapeutic effect of ionizing radiation is due to double-strand breaks in the DNA of tumor cells, which occurs as a result of ionization of surrounding water molecules and the release of free radicals, as well as due to the direct ionization of DNA molecules. The current RT methods allow the use of high doses of radiation, while the surrounding organs and tissues are also exposed to significant exposure. Peculiarities of the pelvic anatomy can explain various radiation injuries to nearby organs, including the bladder, ureters, rectum, which are complicated by urogenital fistulas, post-radiation fibrosis with the formation of hydronephrosis and microcyst. All of these specific complications significantly reduce the quality of life of patients.

Ureteral strictures are a relatively rare complication that occurs after surgery or RT of pelvic tumors with the incidence after 5, 10, 15, 20 and 25 years of 1.0%, 1.2%, 2.2%, 2.5% and 3.3%, respectively [2].

In most cases, ureteral strictures caused by RT are diagnosed late. Their manifestations vary from asymptomatic hydronephrosis to loss of renal function and the development of life-threatening urosepsis [3]. Strictures that develop most often after RT for cervical cancer (CC) usually occur 4–6 cm proximal to the ureteral orifice, near the area that is most exposed to ionizing radiation [4].

Aim. To highlight the relevance and importance of the correct choice of surgical intervention for patients with radiation-induced urinary tract injuries.

Materials and methods. The group of radiation injuries of the urinary tract included 60 patients aged 39–65 years. The distribution of patients by the total radiation dose and the time of development of post-radiation complications, as well as by the method of primary drainage of the upper urinary tract is presented in *tables 1–3*. Taking into account the minimal post-radiation changes in the pelvic tissue, preserved bladder capacity and short ureteral stricture, 41 (68.3%) patients underwent the Boari procedure and ureterovesical anastomosis. Other

Table 1

Distribution of patients by radiation dose

	Total absorbed dose (Gy)					
	До 60	60–100	100–140	Более 140	No data	
Number of patients	6 (10%)	24 (40%)	12 (20%)	9 (15%)	9 (15%)	60 (100%)

Table 2

Distribution of patients by time of development of complications

Time of development of complications	Number of patients	%
Within 1 year	31	51.7
From 1 to 5 years	20	33.3
From 5 to 10 years	5	8.3
After 10 years	4	6.7
Total	60	100

19 (31.7%) patients with various post-radiation injuries of the ureters underwent reconstruction using bowel segments. These patients were included in the study group. The types of intestinal reconstructions are shown in *table 4*.

During the surgical intervention, histological and immunohistochemical (IHC) studies of the distal end of the ureter in the stricture area were performed to assess the true radiation damage. After deparaffinization and dehydration of the sections, IHC testing was performed according to the standard protocol in automatic mode in the BenchMark XT Ventana immunohistostainer (Biovitrum, Russia) to identify diagnostic markers of the regenerative process.

As primary antibodies in all reactions, mouse monoclonal antibodies to contractile proteins (Smooth Muscle Actin, Vimentin) and inflammation markers (CD45R, CD58, CD138, CD20, CD3) from Leica Biosystems Newcastle Ltd, United Kingdom were used. The intensity of staining was assessed according to the manufacturers' recommendations and using a color detection scale: -, no expression, +, weak expression; ++, moderate expression; +++, pronounced expression (high-intensity immunoperoxidase staining).

One month after interventions, nephrostomy drainage/internal stent was removed, and antegrade pyelography was performed to assess the urine passage. After 12 months, computed tomography (CT) with intravenous contrast and dynamic scintigraphy were done to assess renal function.

Results. Impaired urine passage with the development of hydronephrosis was detected in 3 (15.8%) patients. Subsequently, one patient underwent nephrectomy for terminal hydronephrosis and loss of renal function. During follow-up dynamic scintigraphy, slight improvement in renal function was observed in 14 patients ($p<0.05$). In 6 (31.6%) cases, renal function was complete normalized (*table 5*).

Fig. 1 shows a fragment of the ureter with a sharply narrowed lumen, covered with atrophic transitional epithelium. In the wall there is a proliferation of dense fibrous tissue. The wall has pronounced sclerotic changes and foci of chronic infiltration. Before reconstruction, a nephrostomy tibe was put.

Table 3

Type of upper urinary tract drainage

Type of derivation	Number of patients	%
Nephrostomy tube	41	68.3
Ureteral stent	19	31.7

Table 4

Distribution of patients by type of surgical procedure

Side of the intervention	Number of patients	Type of reconstruction	Number of patients (%)
Left ureteral substitution by bowel segment	7	Total ureteroplasty	2 (10.5)
		Substitution of the two lower thirds of the ureter	5 (26.3)
Right ureteral substitution by bowel segment	9	Total substitution of the ureter	3 (15.8)
		Substitution of the two lower thirds of the ureter	6 (31.6)
Bilateral ureteral substitution by bowel segment	3	S-shaped flap	3 (15.8)

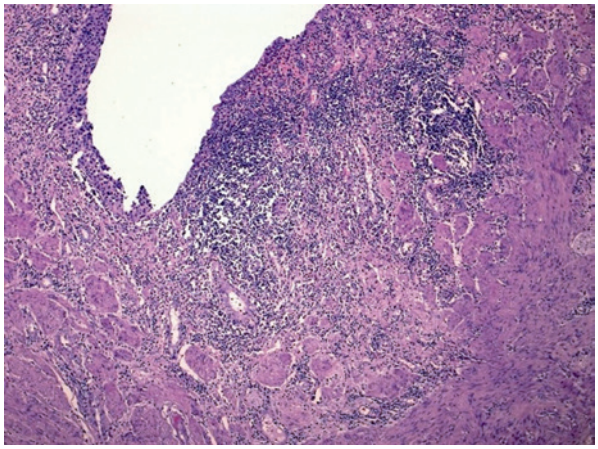

Fig. 1. Histological examination of a ureter after putting of nephrostomy tube. Staining by hematoxylin and eosin, magnification x56

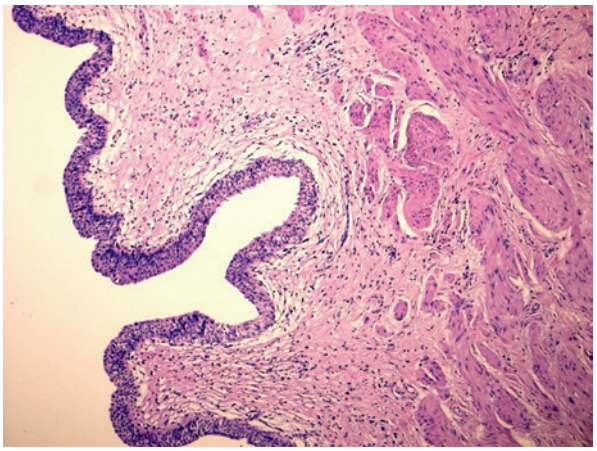

Fig. 2. Histological examination of a ureter fragment after putting of ureteral stent. Staining by hematoxylin and eosin, magnification x56

Fig. 2 shows fragments of the ureter with predominantly fibrous tissue, in the center of which there is an irregularly shaped narrow duct lined with urothelium. The muscular membrane is atrophied with fibrosis; in some areas there is salt deposition. This patient had previously had an internal stent.

Fig. 3 presents the results of IHC, which showed that inflammatory infiltration and the absence of a clear boundary of the stricture zone are more pronounced in patients with an internal ureteral stent. This was not observed in those who had nephrostomy tubes. It was also noted that the early postoperative period in 5 (26.3%) patients was complicated by the development of acute non-obstructive pyelonephritis requiring antibacterial therapy (grade II complication according to the Clavien-Dindo). No other complications were identified in the immediate postoperative period.

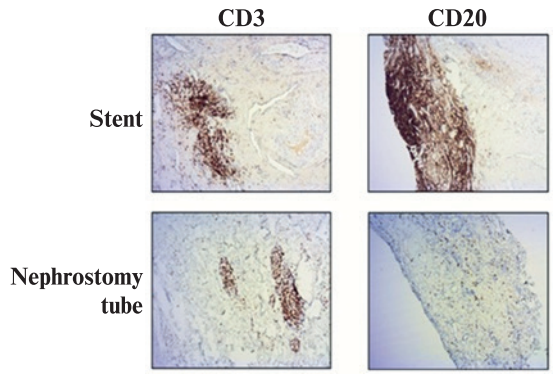

Fig. 3. Immunohistochemical examination of a ureter fragment

Clinical cases

Clinical case No. 1. Patient M., 46 years old. Combined treatment for cervical cancer was performed in 2004. Further, reconstructive surgeries on the urinary tract were done. She had microcyst, ureterostomy on the left and nephrostomy on the right. Considering the reduced bladder capacity and the preserved urethral sphincters, a decision was made to perform cystectomy with a formation of a Studer orthotopic bladder (*Fig. 4*).

A control follow-up did not reveal any urodynamic disorders, and the bladder capacity was sufficient (*Fig. 5*).

Clinical case No. 2. Patient P., 56 years old. A diagnosis is cervical cancer pT2NoMo. Combined treatment (extended hysterectomy + radiation therapy SOD 75 Gy + chemotherapy) was performed in January of 2017. She had microcyst and obliteration of the lower thirds of both ureters with bilateral nephrostomy from 04.2017.

Taking into account the presence of long obliteration in combination with microcyst, in order to restore the urine passage, a decision was made to perform reconstruction using intestinal segment. Bowel substitution of the ureters and bladder with an L-shaped segment of the ileum was performed. CT after 1 year is shown on *Fig. 6.* In the long-term period after 4 years, no urodynamic disorders were detected.

Clinical observation No. 3. The following clinical example demonstrates the erroneous treatment tactics for a patient with severe radiation damage to the urinary tract, who underwent unsuccessful attempts to reconstruct the right ureter using standard procedures.

Patient O., 49 years old. In 2021, combined treatment for cervical cancer was carried out. Initially, extended hysterectomy and pelvic lymphadenectomy was done,

Table 5

Evaluation of renal function and urine passage during follow-up studies

	Improvement (%)	Stabilization (%)	Deterioration (%)	*p*-value
CT	16 (84.2)	–	3 (15.8)	$p<0.05$
Dynamic scintigraphy	14 (73.7)	2 (10.5)	3 (15.8)	$p<0.05$

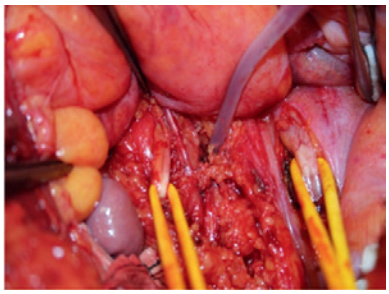

a – cystectomy, dissection of ureters

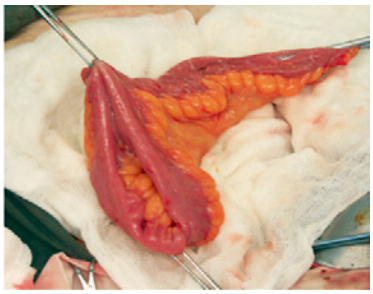

b – ileum segment, formation of orthotopic neobladder

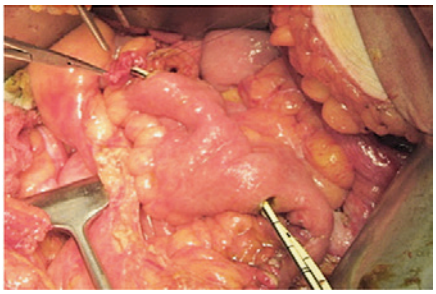

c – intestinal reservoir

Fig. 4. Intraoperative view. Stages of the procedure performed in patient M

followed by combined radiation therapy (external RT 50 Gy + brachytherapy 15 Gy). Subsequently, right-side hydronephrosis and post-radiation stricture of the lower third of the right ureter were diagnosed. A nephrostomy tube was placed.

On 05/24/2022, a laparoscopic ureterovesical anastomosis on the right was performed. On 06/14/2022, the internal ureteral stent was removed. After that, urine passage was not restored; antegrade pyeloureterography revealed a recurrence of the right ureteral stricture (*Fig. 7*).

On 10/04/2022, a repeat intervention was performed, namely lower midline laparotomy, adhesiolysis, and Boari flap technique on the right. Intraoperatively, a filiform ureter of a whitish color was seen (*Fig. 8*).

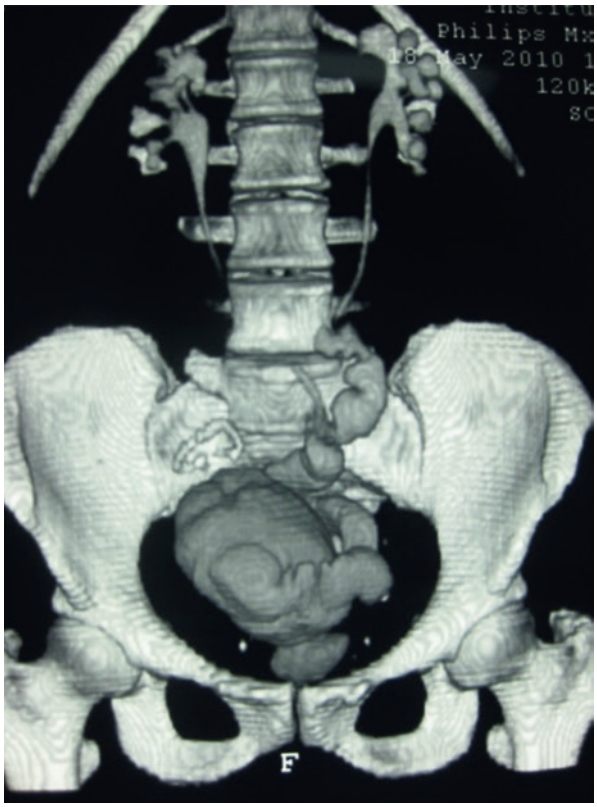

Fig. 5. Follow-up CT

Due to prolonged hyperthermia in the postoperative period, CT of the abdominal cavity and pelvic organs with intravenous contrast was performed, according to which signs of a failure of bladder flap with leakage of a contrast agent into the retroperitoneal space were detected (*Fig. 9*).

To ensure adequate drainage of the upper urinary tract and to prevent urine extravasation, external ureteral stents were placed, which made it possible to close the bladder flap defect (*Fig. 10*).

01/13/2023, according to the results of MRI of the abdominal organs and urinary system with intravenous contrast, there was no urine leak. A pronounced adhesive process was noted in the abdominal cavity.

External ureteral stents and a urethral catheter were removed in stages, but the patient showed a progressive decrease in bladder capacity to 50 ml and deterioration of hydronephrosis. During the follow-up, microcyst and bilateral hydronephrosis were diagnosed, which required bilateral nephrostomy. On March 6, 2023, a ureterovesical anastomosis was performed with an ileal segment. External

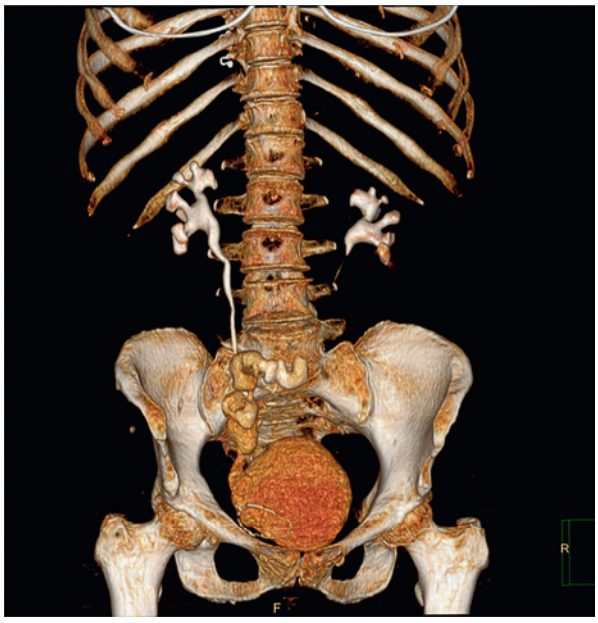

Fig. 6. CT after 1 year. No impairments of urine passage were detected

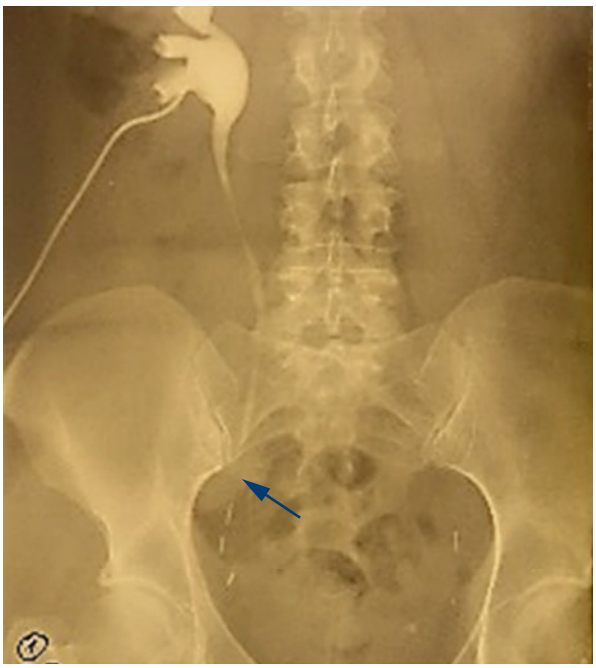

Fig. 7. Antegrade pyelography. Recurrent ureteral stricture (indicated by the arrow)

ureteral stents and a urethral catheter were removed in stages. After removal of the urethral catheter, the patient continued to urinate in small portions and had pain during voiding. Cystoscopy revealed excessive granulation tissue in the area of the anastomosis of the bladder with an artificial intestinal reservoir. A transurethral resection was performed on April 19, 2023, which allowed to achieve adequate communication of the artificial urinary reservoir with the bladder. Conservative therapy and two courses of hyperbaric oxygen therapy increased the capacity of the artificial urinary reservoir to 250 ml.

During follow-up, no impairment of upper urinary tract urodynamics were observed (*Fig. 11*). In our opinion, the reason for the failure of previous reconstruction the ureter using bladder flap was the underestimated progression of post-radiation fibrosis of the pelvic tissue and recurrent urinary infection resistant to most antibiotics.

Discussion. Currently, radiation therapy, both as monotherapy and in combination with surgical treatment, is performed for the majority of patients with gynecologic tumors. In particular, according to L.I. Krikunova (2004), radiation therapy is used in more than 90% of patients with cervical cancer [5]. The incidence of urological complications of radiation therapy for cervical cancer ranges from 0.6 to 46.3% [6–10].

Long or total radiation damage to the urinary tract is a complex problem in reconstructive urology, considering irreversible changes in tissues due to ionizing radiation that have lost their plastic properties (D.V. Kan, 1986) [11, 19]. The use of "standard" techniques, such as ureterovesical anastomosis or Boari operation, for long ureteral strictures rarely leads to success, as evidenced by our histological and immunohistochemical studies of biopsy specimens of irradiated tissues. In this regard, most authors refuse attempts to restore the urinary tract by performing substitution reconstruction, giving preference to various methods of supra-vesical urine

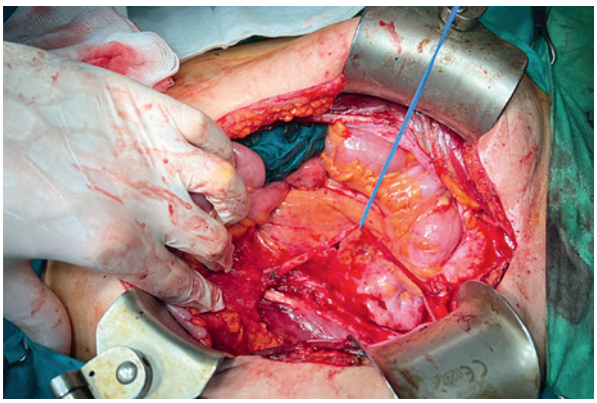

Fig. 8. Intraoperative view of Boari procedure. Vessel loop is placed around the isolated narrow ureter

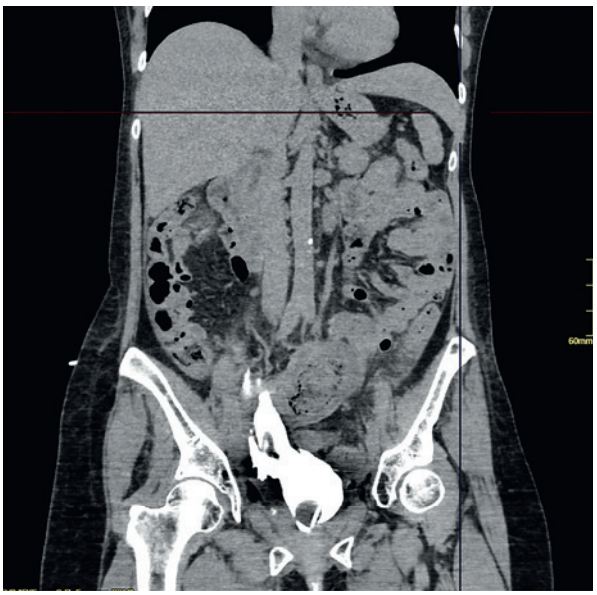

Fig. 9. Contrast-enhanced CT. Bladder defect with urine extravasation into the retroperitoneal space



Fig. 10. Plain urography. Ureteral stents are put

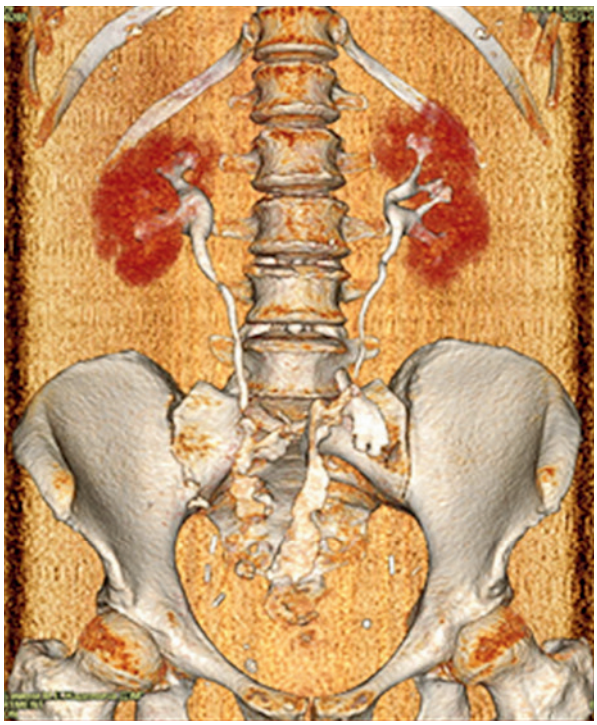

Fig. 11. Follow-up CT – unimpaired urine passage from the upper urinary tract

diversion, such as ureterostomy [12], nephrostomy [8], transverse colon conduit [13-16] or Bricker conduit [17, 18]. Before reconstructive procedures, in the absence of cancer recurrence, preference should be given to putting nephrostomy tubes and avoid the ureteral stents, which aggravate the inflammatory process in the ureters. The choice in favor of percutaneous nephrostomy, in our opinion, ensures adequate urine outflow and favors the preservation of renal tissue, and also causes some improvement in renal function in all patients during follow-up dynamic scintigraphy. This is confirmed by the results of the IHC study.

Reconstruction of the urinary tract after radiation therapy requires to find the optimal material for substitution and proper reconstructive technique. Proper diagnostics, determination of treatment tactics and improvement of the quality of life of patients who have undergone reconstructive surgery for radiation injuries of the urinary tract remain urgent problems of modern urology.

Conclusion. Based on the extensive experience of two centers and long-term postoperative follow-up, we have proved an efficiency of our approaches to surgical treatment of socially significant radiation-induced injuries of the ureter, the implementation of which will significantly improve medical and social rehabilitation for this category of patients. Our data can serve as a basis for the development of guidelines and protocols for the management of patients with radiation injuries of the urinary tract.

REFERENCES

1. American Cancer Society. Cancer Facts & Figures 2018. Available at www. cancer.org/research/cancer-facts-statistics/all-cancer-facts-figures/cancer-facts-figures-2018. html. Accessed January 8, 2018.
2. *McIntyre J.F., Eifel P.J., Levenback C., Oswald M.J.* Ureteral stricture as a late complication of radiotherapy for stage IB carcinoma of the uterine cervix. Cancer. 1995;75(3):836-43. doi: 10.1002/1097-0142(19950201)75:3<836::aid-cncr2820750315>3.0.co;2-a. PMID: 7828135.
3. *Demanes D.J., Banerjee R., Cahan B.L., Lee S.P., Park S.J., Fallon J.M., Reyes P., Van TQ, Steinberg ML, Kamrava MR.* Ureteral stent insertion for gynecologic interstitial high-dose-rate brachytherapy. Brachytherapy. 2015;14(2):245–251. Doi: 10.1016/j.brachy.2014.11.013. Epub 2014 Dec 31. PMID: 25556864.
4. *Wit E.M., Horenblas S.* Urological complications after treatment of cervical cancer. Nat Rev Urol. 2014;11(2):11–27. Doi: 10.1038/nrurol.2013.323. Epub 2014 Jan 28. PMID: 24473416.
5. *Krikunova L.I.* Radiation therapy of uterine cancer. Practical oncology. 2004;5(1):34–36. Russian (Крикунова Л.И. Лучевая терапия рака матки. Практическая онкология. 2004;5(1):34–36).
6. *Okadome M., Saito T., Kitade S., Ariyoshi K., Shimamoto K., Kawano H., Minami K., Nakamura M., Shimokawa M., Okushima K., Kubo Y., Kunitake N.* Renal function and urological complications after radical hysterectomy with postoperative radiotherapy and platinum-based chemotherapy for cervical cancer. Jpn J Clin Oncol. 2018;48(2):115–123. Doi: 10.1093/jjco/hyx160. PMID: 29136246.
7. *Buglione M., Toninelli M., Pietta N. et al.* Post-radiation pelvic disease and ureteral stenosis: physiopathology and evolution in the patient treated for cervical carcinoma. Review of the literature and experience of the Radium institute. Arch. Ital. Urol. Androl. 2002;74(1):6–11.
8. *Beller H.L., Rapp D.E., Zillioux J., Abdalla B., Duska L.R., Showalter T.N., Krupski T.L., Cisu T., Congleton J.Y., Schenkman N.S.*. Urologic Complications Requiring Intervention Following High-dose Pelvic Radiation for Cervical Cancer. Urology. 2021;151:107–112. Doi: 10.1016/j.urology.2020.09.011. Epub 2020 Sep 20. PMID: 32961221.
9. *Toia B., Seth J., Ecclestone H., Pakzad M., Hamid R., Greenwell T., Ockrim J.* Outcomes of reconstructive urinary tract surgery after pelvic radiotherapy. Scand J Urol. 2019;53(2-3):156–160. Doi: 10.1080/21681805.2019.1611631. Epub 2019 May 15. PMID: 31092116.
10. *Welk B., Wallis C., D'Souza D., McGee J., Nam R.K.* A Population-Based Assessment of Urologic Procedures and Operations After Surgery or Pelvic Radiation for Cervical Cancer. Int J Gynecol Cancer. 2018;28(5):989–995. Doi: 10.1097/IGC.0000000000001266. PMID: 29664839.
11. *Kan D.V.* Handbook of obstetric and gynecological urology. M.: Medicine, 1986. 488 p. Russian (Кан Д.В. Руководство по акушерской и гинекологической урологии. М.: Медицина, 1986. 488 с.).
12. *Pomer S., Karcher G., Simon W.* Cutaneous ureterostomy as last resort treatment of intractable haemorrhagic cystitis following radiation. Br J Urol. 1983;55(4):392–394. Doi: 10.1111/j.1464-410x.1983.tb03329.x. PMID: 6883044.
13. *Schmidt J.D., Hawtrey C.E., Buchsbaum H.J.* Transverse colon conduit: a preferred method of urinary diversion for radiation-treated pelvic malignancies. J Urol. 1975;113(3):308–313. Doi: 10.1016/s0022-5347(17)59469-0. PMID: 1090758.
14. *Beckley S., Wajsman Z., Pontes J.E., Murphy G.* Transverse colon conduit: a method of urinary diversion after pelvic irradiation. J Urol. 1982;128(3):464–468. Doi: 10.1016/s0022-5347(17)52999-7. PMID: 7120546.
15. *Ahyai S.A., Sayedahmed K., Engel O., Chun F., Dahlem R., Fisch M.* Harnableitung und Dickdarm : Das Transversumconduit und der Transversumpouch [Urinary diversion and colon: transverse conduit and transverse pouch]. Urologe A. 2012;51(7):937–946. German. Doi: 10.1007/s00120-012-2907-5. PMID: 22772492.
16. *Pycha A, Trenti E.* Hohe Harnableitung nach Bestrahlung im kleinen Becken [High urinary diversion after irradiation to the lesser pelvis]. Urologe A. 2020;59(4):4169425. German. Doi: 10.1007/s00120-020-01156-2. PMID: 32130447.
17. *Ungar L., Palfalvi L., Novak Z.* Primary pelvic exenteration in cervical cancer patients. Gynecol Oncol. 2008;111(2 Suppl):S9–12. Doi: 10.1016/j.ygyno.2008.07.041. Epub 2008 Sep 5. PMID: 18775558.
18. *Pokharkar A., Kammar P., D'souza A., Bhamre R., Sugoor P., Saklani A.* Laparoscopic Pelvic Exenteration for Locally Advanced Rectal Cancer, Technique and Short-Term Outcomes. J Laparoendosc Adv

Surg Tech A. 2018;28(12):1489–1494. Doi: 10.1089/lap.2018.0147. Epub 2018 May 9. PMID: 29741977.

19. *Loran O.B., Sinyakova L.A., Guspanov R.I.* Radiation damage to the organs of the urinary system in oncogynecological diseases. M.: Medical Information Agency, 2019. 120 p. Russian (Лоран О.Б., Синякова Л.А., Гуспанов Р.И. Лучевые повреждения органов мочевой системы при онкогинекологических заболеваниях. М.: Медицинское информационное агентство, 2019. 120 с.).

Received 20.01.2024
Accepted 02.03.2024
Financing source: Absents

Author information:

Loran O.B. –Academician of RAS, Ph.D., MD, professor, Chief of Department of Urology and Surgical Andrology, Russian Medical Academy of Continuous Professional Education, Moscow, Russia; e-mail: olegloran@gmail.com. ORCID: 0000-0002-7531-1511

Guspanov R.I. – Ph.D., associate professor at the Department of Urology and Andrology of Pirogov Russian National Research Medical University, Moscow, Russia; e-mail: uroguspanov@yandex.ru. ORCID: 0000-0002-2944-2668

Kotov S.V. – Ph.D., MD, professor, Head of the Department of Urology and Andrology of Pirogov Russian National Research Medical University, Moscow, Russia, urokotov@mail.ru. ORCID: 0000-0003-3764-6131

Seregin A.V. – Ph.D., MD, professor, Head of the Urologic Department No41 of S.P. Botkin city clinical hospital, Moscow, Russia; e-mail: av_seregin@mail.ru. ORCID: 0000-0002-5842-7344

Morozov A.D. – Ph.D., urologist of the Urologic Department No41 of S.P. Botkin city clinical hospital, Moscow, Russia

Bogdanov D.A. – Ph.D. student at the Department of Urology and Andrology of Pirogov Russian National Research Medical University, Moscow, Russia. ORCID: 0000-0001-6847-5684