SYSTEMATIC REVIEW

©TEAM OF AUTHORS, 2024

V.A. Malkhasyan[1,2], A.G. Martov[3,4], N.K. Gadzhiev[5], S.O. Sukhikh[2], B.L. Grigoryan[1], D. Yu. Pushkar[1,2]

COMPLICATIONS OF FLEXIBLE URETERORENOSCOPY: A SYSTEMATIC REVIEW

[1]Russian University of Medicine, Moscow, Russia; [2]Botkin City Clinical Hospital, Moscow, Russia; [3]A.I.Burnazyan Federal Medical Biophysical Center of the FMBA of Russia, Moscow, Russia; [4]M.V. Lomonosov Medical Research and Educational Center Moscow State University, Moscow, Russia; [5]N.I.Pirogov High Medical Technologies Clinic, Saint Petersburg State University, Saint Petersburg, Russia

Corresponding author: V.A. Malkhasyan – M.D., Dr.Med.Sci.; Professor of the Department of Urology, Russian University of Medicine; Head of Urology Department №67, Botkin City Clinical Hospital, Moscow, Russia; e-mail: vigenmalkhasyan@gmail.com

Retrograde intrarenal surgery (RIRS) is a type of endoscopic intervention on the kidneys performed using a semi-rigid or flexible fiber optic endoscope. RIRS is recommended by national clinical guidelines for stone management sized up to 20 mm. However, like any other surgical intervention, RIRS is associated with the risk of complications. Complications affect the patient's quality of life, and cause additional costs determined by prolonged hospital stay and subsequent treatment. This systematic review is devoted to the complications of RIRS, methods of their prevention and treatment, which should make possible to increase the effectiveness and safety of care for patients with urolithiasis.

K e y w o r d s: retrograde intrarenal surgery, flexible ureterorenoscopy, fURS, complications

The authors declare no conflict of interest. For citation: Malkhasyan V.A., Martov A.G., Gadzhiev N.K., Sukhikh S.O., Grigoryan B.L., Pushkar D.Yu. Complications of flexible ureterorenoscopy: a systematic review. Urologiia. 2024;2:105-111.
Doi: https: //dx.doi.org/10.18565/urology.2024.2.105-111

Introduction. Urolithiasis is one of the most common urologic diseases, the peak of which occurs in the third and fourth decades of life [1]. Treatment strategy varies from observation to surgical removal of the stone. The types of surgical intervention depend on the stone number, size, density and location. Over the past decades, "open" surgery has been almost completely replaced by minimally invasive endoscopic procedures. Percutaneous nephrolithotomy has become the most widely used treatment option for upper urinary tract stones larger than 2 cm. This method has high efficacy, but is associated with the risk of developing serious complications, such as bleeding, infections and damage to adjacent organs. In this regard, in recent years, flexible ureteroscopy has been actively introduced into clinical practice as a less traumatic and safe option. Technical advances in the endoscopic instruments, the emergence of digital and disposable endoscopes, and the miniaturization of instruments contribute to the constant expansion of indications for retrograde intrarenal surgery (RIRS) [2]. However, despite the presumed safety, according to many studies, RIRS is also associated with a number of complications, the incidence of which can reach 8% [3–5]. In our systematic review, we analyzed the published data, formulating recommendations to help predict, prevent, and effectively overcome complications of flexible ureteroscopy. We carried out a systematic search of publications from 2007 to September 2022 (over the past 15 years) dedicated to complications of RIRS in PubMed, Google Scholar, and Scopus. This review was conducted according to the PRISMA checklist (*Fig. 1*). The search strategy included free-text using the following key words: ureterorenoscopy, retrograde intrarenal surgery, flexible ureteroscopy, lithotripsy, intraoperative complication, postoperative complication, fURS, RIRS, mortality.

When forming the search query, studies devoted to the pediatric patient population and those published in languages other than English were excluded.

Two researchers carried out the search independently. Eligible studies were read in full-text. Their reference lists were also reviewed for possible additional publications. After full-text screening, duplicates were excluded. Any disagreements regarding the inclusion or exclusion of preselected studies for the systematic review or any other disagreements during the review process were resolved by discussion or involving a third author.

The initial search identified 278 articles. After removing duplicates, the following types of publications were further excluded: commentaries to articles, conference abstracts, articles without abstracts, description of clinical cases. The remaining 47 publications included 21 clinical trials, 16 literature reviews, and 10 meta-analyses. After reviewing the abstracts, 37 publications were selected for further analysis. Of priority interest were studies performed on a large number of patients (n> 50), containing the Clavien–Dindo classification of complications or having a detailed description of complications that can be easily assessed using this classification. Publications devoted to methods of eliminating complications were also of interest.

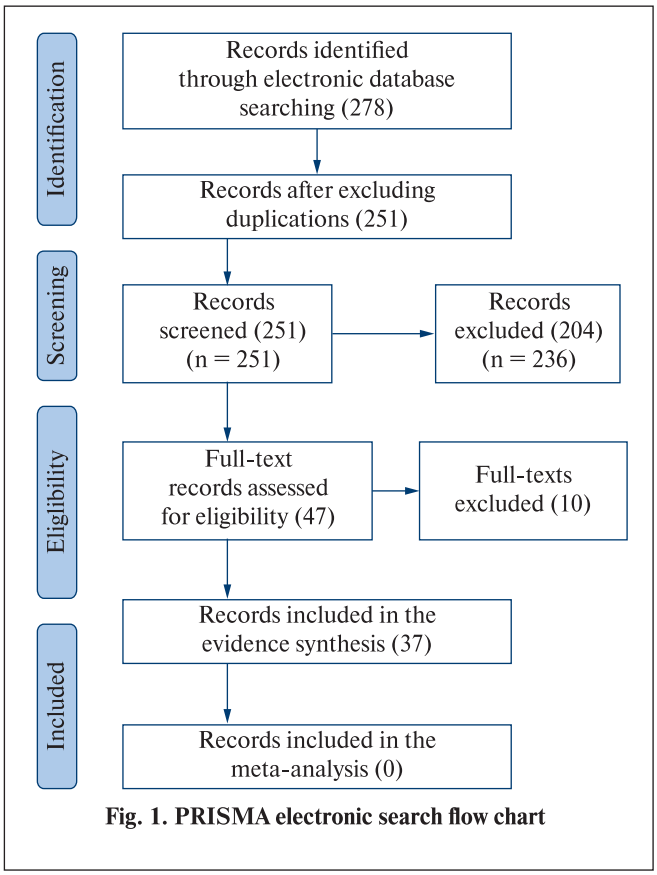

Fig. 1. PRISMA electronic search flow chart

Clavien–Dindo classification of complications. The standardized Clavien–Dindo classification of surgical complications is used as a simple and widely used tool for assessing and recording surgical complications. In most literature sources, this classification is used to describe and compare complications of specific surgical procedures [6].

The Clavien–Dindo classification, modified for assessing complications of ureteroscopy and RIRS, was first used by Mandal et al. in 2012 [7]. The result of this study was the addition of complications that were not mentioned by previous researchers in retrospective analyses. They included hematuria, transient increase in serum creatinine levels, and fever. All of the above phenomena resolved spontaneously without pharmacological treatment or additional surgical interventions. Currently, the modified Clavien-Dindo classification allows for a more subtle assessment of the treatment outcomes and demonstrates a more complete description of the postoperative course.

In the modified Clavien-Dindo classification, five degrees of complications are distinguished, which can be divided into three groups: infectious, traumatic, and hemorrhagic (see table). Using this scale for assessing adverse events in a retrospective study, E. Ogreden et al. in 2016 analyzed 811 patients. As a result, the first quantitative distribution of complications of semirigid ureteroscopy was developed [8]. Complications of RIRS can be classified as infectious, hemorrhagic, and traumatic.

Table

Modified Clavien-Dindo classification of complications of flexible URS and the results of a retrospective study by E. Ogreden et al. with the percentage of adverse events

Grade	Complication	*n* (%)
I	Fever	83 (10.2)
	Transient increase in creatinine	3 (0.37)
	Transient hematuria	110 (13.6)
	Persistent hematuria	46 (5.7)
	Total complications	242 (29.8)
II	Blood transfusion	2 (0.24)
	Urinoma requiring urinary tract drainage with a stent	56 (6.9)
	Total complications	58 (7.1)
IIIa	Urinoma requiring urinary tract drainage with a stent	18.2 (2.2)
	Bladder hemotamponade	11 (1.4)
	Ureteral mucosal injury	41 (5.0)
	Total complications	70 (8.6)
IIIв	Ureteral stent migration	16 (1.9)
	Stone migration	30 (3.7)
	Ureteral perforation	37 (4.6)
	Ureteral avulsion	7 (0.86)
	Ureteral stricture	0 (0)
	Total complications	90 (11)
IVa	Myocardial infarction	0 (0)
	CKD	0 (0)
	Total complications	0 (0)
IVв	Urosepsis	10 (1.2)
	Multiple organ failure	0 (0)
	Total complications	10 (1.2)
V	Death	0 (0)
Total number		470 (5.9)

Infectious complications. For flexible URS, they include hyperthermia, acute pyelonephritis, systemic inflammatory response syndrome (SIRS) and sepsis. The latter is a dangerous complication that can lead to the death. In a survey of 11 endourologists with extensive experience in performing flexible URS, carried out by L. Cindol et al., 4 cases of urosepsis with a lethal outcome were identified [9].

According to various publications, a rate of infectious complications is about 7.7–8.4%. SIRS can develop in 1.7–4.4% of cases, while the incidence of urosepsis is within 0.7–1.3% [4, 10–12]. According to F. Berardinelli et al., the overall rate of infectious complications, including hyperthermia (4.4%), SIRS (1.7%) and sepsis (0.7%), can reach 7.7% even despite preoperative antibiotic prophylaxis [9]. In a retrospective study, S. Fan et al. analyzed 227 patients who underwent flexible URS [10]. The authors showed that in the absence of residual fragments ("stone free") in 81.9% of patients, the incidence of infectious complications was 8.4%. The most common postoperative complication that does not require reoperation is fever, which can have various origin. On average, fever occurs in 9% of patients with negative urine culture even if preoperative antibiotic prophylaxis is used [8, 13–16]. The main risk factors for infectious complications, according to the literature data:

- female gender,
- diabetes mellitus,
- duration of the procedure over 60 min,
- stone size over 2 cm,
- infectious stones (struvites),
- bacteriuria,
- leukocyturia,
- history of urinary infection,
- presence of residual fragments,
- intraoperative increase in intrarenal pressure (IRP) ⩾40 cm H_2O,
- volume and flow rate of irrigation fluid [10, 12, 17–22].

The development of infectious complications is associated with the increased IRP [23]. This leads to the development of pyelovenous reflux, which results in the release of the contents of the collecting system directly into the bloodstream. In an experimental study by Loftus et al. on an animal model, it was shown that elevated IRP increases the likelihood of bacteremia and contamination of parenchymatous organs such as the kidneys, liver, and spleen with microorganisms contained in the irrigation fluid [24]. According to a randomized study by Omar et al., high IRP leads to an increase in the frequency of a systemic inflammatory response by approximately 30% [25].

A number of authors showed that the IRP during flexible URS is significantly higher compared to percutaneous procedures and varies in the range of 40.8–199.35 cm H_2O [26]. Normal IRP fluctuates within 0–20 cm H_2O, and its increase depends on many factors. Thus, even the passage of a ureteroscope into the collecting system without irrigation can lead to an increase in IRP by 30 cm H_2O due to obstruction of the ureteral lumen, and active irrigation with a manual pump can lead to an increase in IRP from 156.4 to 557.6 cm H_2O depending on its intensity [27]. As indicated earlier, a specific role in the development of infectious complications belongs to the pyelovenous reflux. According to experimental studies, it occurs with a persistent increase in IPP to 74 cm H_2O and higher for 20 minutes [28]. Thus, the most rational way to control infectious complications seems to be the control of IRP as the main pathogenetic mechanism. One of the effective methods for controlling IRP is the use of a ureteral access sheath (UAS). The study of Tokas et al. showed that when using UAS, IRP usually does not exceed 30 cm H_2O with an irrigation fluid pressure of ⩽100 cm H_2O [25]. The use of UAS reduces IRP, while improving the visibility, which increases the efficiency of the procedure [29–31]. UAS allow to maintain a stable IRP in safe range even when using a hand pump. According to the Rehman et al., UAS of 12–14 Fr or more allows for stabilization of IRP <20 cm H_2O [32, 33], which in turn leads to a decrease in the incidence of infectious complications [34].

Another significant risk factor for infectious complications is the duration of procedure. The study by Xu et al. showed that the risk of infectious complications increases by 11.1 times if intervention lasts more than 60 min [35]. Accordingly, with a large stone, the duration of procedures increases, which is associated with a high risk of infectious complications.

No less significant risk factors for infectious complications and sepsis are asymptomatic bacteriuria, the presence of obstruction or a ureteral stent [20, 36, 37]. According to the study by Wang et al., the use of flexible URS in patients with upper urinary tract obstruction is associated with a higher risk of sepsis than with percutaneous access [20]. Such risks can be explained by the impaired urine passage and, as a result, misleading results of urine culture, indicating sterility, while the pelvis can be contaminated with pathogens. Other authors completely dispute the value of bacteriological examination of urine from the bladder, demonstrating much greater sensitivity of the results of urine from the renal pelvis and the stone [38].

A ureteral stent, being a foreign body, is also considered by many authors as a risk factor for infectious complications. According to a large multicenter study, the dwelling time more than 2 months increases the risk of developing infectious complications, and duration of stenting more than 4 months triples the risks [39]. In the study of Nevo et al., an increased risk of sepsis was demonstrated in patients with a ureteral stent; in addition, the risks of sepsis depended on the dwelling time. Thus, an increased probability of sepsis was observed in cases where the duration of stenting was more than 1 month [40].

One of the most popular preventive measures is the preoperative antibacterial therapy. A number of studies have shown that preoperative antibacterial prophylaxis with a single dose leads to a decrease in the incidence of bacteriuria, leukocyturia and infectious complications. Intravenous antibiotic prophylaxis is not superior to oral in terms of reducing the incidence of urinary tract infections [41, 42]. Zisman et al. mentioned a higher risk of developing urosepsis in patients with a positive urine culture, suggesting as a preventive measure an augmentation of antibacterial therapy (adding a second antibiotic) [43]. Thus, based on the analysis of modern literature, the following recommendations can be given to ensure the safety of RIRS: selection of patients based on risk factors, mandatory use of UAS to maintain IRP at a level of less than 40 cm H_2O, limiting the duration of the procedure to 1 hour in high-risk patients, minimizing

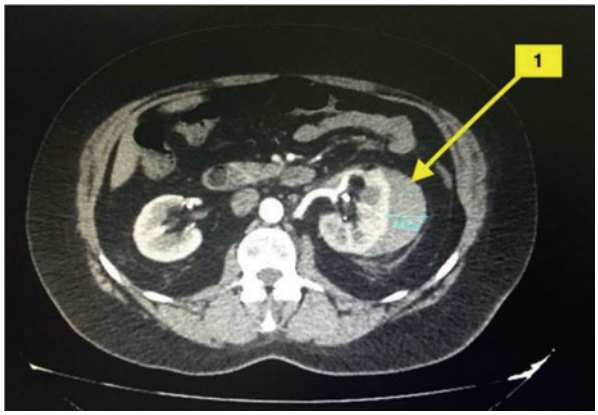

Fig. 2. Contrast-enhanced computed tomography of the urinary system, 1 – subcapsular hematoma of the left kidney after flexible URS

the dwelling stent time before intervention (less than 1 month), routine use of antibiotic prophylaxis, elimination of upper urinary tract obstruction as the first stage of treatment using the results of pelvic urine culture and stone culture in those with impaired urine passage.

Hemorrhagic complications. The most common hemorrhagic complications of RIRS include hematuria and a subcapsular hematoma (*Fig. 2*). According to the literature, hematuria is observed in 7-10% of patients, while the incidence of hematomas does not exceed 0.5% [44-46].

In most patients, subcapsular hematoma is asymptomatic, but it can present with pain and a palpable mass in the lumbar region, fever and a decrease in hemoglobin levels.

In their analysis, Bai et al. showed that the incidence of renal subcapsular hematoma was 0.4% (in 11 patients out of 2848) [41]. Chiu et al. reported a similar incidence, 0.36% (4/ 1114 patients) [40]. In a meta-analysis of 7 randomized studies that included 8929 patients, which was carried out by L. Whitehurst et al., subcapsular hematoma in the postoperative period was found in 0.45% of cases (0.15–8.9%) [47]. At the same time, surgical intervention was required in only 7 (17.5%) patients. In the remaining cases, the hematoma resolved with conservative therapy, which consisted of antibiotics and blood transfusions (22.55%). Percutaneous drainage of the hematoma was performed in 27.5% of cases. Among the 7 patients who required surgical treatment, two underwent angiography, one of whom subsequently had nephrectomy, while in three patients open revision with drainage of the paranephric hematoma was done. The authors noted one lethal outcome. Risk factors for renal hematoma include:

- chronic kidney disease [42, 48],
- ureteral obstruction due to hydronephrosis (ex vacuo bleeding during renal decompression),
- duration of the procedure longer than 41 min,
- patient body mass index <18.5 kg/m^2,
- renal parenchyma thickness less than 1 cm,
- anticoagulant use,
- high IRP ⩾30–40 cm H_2O,

Minor transient hematuria is the most common hemorrhagic complication after flexible URS. According to literature, the incidence of this complication ranges from 7.1 to 19.1% [7, 34]. Predisposing factors include stone size greater than 1.5 cm, high stone density, and use of a large-size UAS. In most cases, patients with transient hematuria do not require active treatment. Hematuria that presents for more than 3 days is classified as persistent and requires examination to identify its source.

The main mechanisms for the development of hemorrhagic complications include forniceal rupture, trauma to the ureteral mucosa or renal papilla during laser lithotripsy. As noted above, forniceal rupture occurs due to high IRP. According to animal studies, it may occur at IRP values of 81.6–95.2 cm H_2O in rabbits and at 272 cm H_2O in pigs [49]. Thus, the main efforts aimed at preventing hemorrhagic complications should be a maintain of a safe IRP level in order to prevent forniceal rupture.

Traumatic complications. The main types include ureteral damage and stricture [50].

The main mechanism of ureteral damage is the passage of an instrument or UAS, especially in case of ureteral deviation and edema, or at level of anatomical narrowings. Due to the narrowness of the ureteral lumen, a surgeon sometimes does not have the ability to pass the instrument or UAS without resistance, and forcing the passage in such cases almost inevitably leads to ureteral trauma.

The most frequently used classification of ureteral damage is proposed by Traxer et al., which is based on the endoscopic picture [51]. According to this classification, there are 5 degrees of ureteral damage. Grade 0 indicated no lesion or only mucosal petechiae, grade 1 represented mucosal erosion or a mucosal flap without smooth muscle injury, grade 2 involved both the mucosa and smooth muscle while sparing the adventitia, grade 3 denoted ureteral perforation encompassing the full thickness of the ureteral wall, including the adventitia, and grade 4 indicated complete ureteral avulsion with a disruption of its continuity. The same group of authors demonstrated that ureteral pre-stenting can reduce the risk of its damage by about 7 times, which is associated with passive dilation and a decrease in tissue resistance. Another study of Jessen et al. also demonstrated the positive role of ureteral pre-stenting [52]. From 565 patients who underwent flexible URS, pre-stenting was performed in 323 cases, while 242 patients did not have a stent preoperatively. According to the results, pre-stenting had a positive effect on the stone-free rate (86% vs. 74%) and the frequency of complications (6.5% vs 14.5%), while the duration of the procedure did not differ significantly (55 ± 36 min vs. 61 ± 35 min). In the group without pre-stenting, ureteral injuries were detected significantly more often (10.7% vs. 3.1%).

In addition to reducing the frequency of ureteral injuries, a number of authors note that pre-stenting reduces the time of procedure, which is associated with a reduction of manipulations during passage ureteroscope to the kidney [53]. Even ureteral injuries lead to the formation of strictures, data from a number of authors show that the incidence of strictures in patients with grade 3 ureteral injuries caused by the passage of UAS does not differ from patients without ureteral injuries and is 1.8% [54]. A study of Aykanat showed that the use of 12/14 Fr UAS increases the risk of ureteral injury without influencing on the incidence of ureteral stricture [55]. Authors of a systematic review of 28 studies concluded

that there is no relationship between ureteral injuries and ureteral strictures.

Available meta-analyses support the pre-stenting, confirming its positive role in reducing the risk of ureteral injury and increasing the likelihood of successful instrument passage [56–58]. The dwelling stent time required for passive dilation remains a controversial issue. According to animal studies, ureteral aperistalsis occurs as early as the fifth day of stent placement [59]. Thus, modern literature supports pre-stenting before stone removal for preventing ureteral damage.

RIRS is an effective and minimally invasive option for treating upper urinary tract stones. In order to minimize the risk of complications, it is necessary to assess risk factors preoperatively and carefully select patients. The current literature demonstrates a positive role in preventing complications of such measures as stone and pelvic urine culture, using UAS, pre-stenting of the ureter, minimizing dwelling stent time and limiting the duration of the procedure.

REFERENCES

1. *Gadzhiev N., Prosyannikov M., Malkhasyan V., Akopyan G., Somani B., Sivkov A., et al.* Urolithiasis prevalence in the Russian Federation: analysis of trends over a 15-year period. World J Urol. 2021;39(10):3939-3944. https://doi.org/10.1007/s00345-021-03729-y.
2. *Danilovic A., Torricelli F., Marchini G.S., Batagello C., Vicentini F.C., Traxer O., et al.* Residual stone fragments after percutaneous nephrolithotomy: shockwave lithotripsy vs. retrograde intrarenal surgery. 2020. Journal of Endourology. 2021;35(5):609-614. https://doi.org/10.1089/end.2020.0868.
3. *Geraghty R., Abourmarzouk O., Rai B., Biyani C.S., Rukin N.J., Somani B.K.* Evidence for Ureterorenoscopy and Laser Fragmentation (URSL) for Large Renal Stones in the Modern Era. Curr Urol Rep. 2015;16(8):54. https://doi.org/10.1007/s11934-015-0529-3
4. *de la Rosette J., Denstedt J., Geavlete P., Keeley F., Matsuda T., Pearle M., et al.* The clinical research office of the endourological society ureteroscopy global study: indications, complications, and outcomes in 11,885 patients. J Endourol. 2014;28(2):131-139. https://doi.org/10.1089/end.2013.0436
5. *Gauhar V., Chew B.H., Traxer O., Tailly T., Emiliani E., Inoue T., et al.* Indications, preferences, global practice patterns and outcomes in retrograde intrarenal surgery (RIRS) for renal stones in adults: results from a multicenter database of 6669 patients of the global FLEXible ureteroscopy Outcomes Registry (FLEXOR). World J Urol. 2023;41(2):567-574. https://doi.org/10.1007/s00345-022-04257-z
6. *Bolliger M., Kroehnert J.A., Molineus F., Kandioler D., Schindl M., Riss P.* Experiences with the standardized classification of surgical complications (Clavien-Dindo) in general surgery patients. Eur Surg. 2018;50(6):256-261. https://doi.org/10.1007/s10353-018-0551-z
7. *Mandal S., Goel A., Singh M.K., Kathpalia R., Nagathan D.S., Sankhwar S.N., et al.* Clavien classification of semirigid ureteroscopy complications: a prospective study. Urology. 2012;80(5):995-1001. https://doi.org/10.1016/j.urology.2012.05.047
8. *Öğreden E., Oğuz U., Demirelli E., Benli E., Sancak E.B., Gülpinar M.T., et al.* Categorization of ureteroscopy complications and investigation of associated factors by using the modified Clavien classification system. Turk J Med Sci. 2016;46(3):686-694. https://doi.org/10.3906/sag-1503-9
9. *Cindolo L., Castellan P., Scoffone C.M., Cracco C.M., Celia A., Paccaduscio A., et al.* Mortality and flexible ureteroscopy: analysis of six cases. World J Urol. 2016;34(3):305-310. https://doi.org/10.1007/s00345-015-1642-0
10. *Demir D.O., Doluoglu O.G., Yildiz Y., Bozkurt S., Ayyildiz A., Demirbas A.* Risk Factors for Infectious Complications in Patients Undergoing Retrograde Intrarenal Surgery. J Coll Physicians Surg Pak. 2019;29(6):558-562. https://doi.org/10.29271/jcpsp.2019.06.558
11. *Berardinelli F., De Francesco P., Marchioni M., Cera N., Proietti S., Hennessey D., et al.* Infective complications after retrograde intrarenal surgery: a new standardized classification system. Int Urol Nephrol. 2016;48(11):1757-1762. https://doi.org/10.1007/s11255-016-1373-1.
12. *Fan S., Gong B., Hao Z., Zhang L., Zhou J., Zhang Y., et al.* Risk factors of infectious complications following flexible ureteroscope with a holmium laser: a retrospective study. Int J Clin Exp Med. 2015;8(7):11252-9.
13. *Dybowski B., Bres-Niewada E., Rzeszutko M., Tkaczyk A., Woźniak B., Wójcik M., et al.* Risk factors for infectious complications after retrograde intrarenal surgery – a systematic review and narrative synthesis. Cent European J Urol. 2021;74(3):437-445. https://doi.org/10.5173/ceju.2021.250
14. *Li T., Sun X.Z., Lai D.H., Li X., He YZ.* Fever and systemic inflammatory response syndrome after retrograde intrarenal surgery: Risk factors and predictive model. Kaohsiung J Med Sci. 2018;34(7):400-408. https://doi.org/10.1016/j.kjms.2018.01.002
15. *Senocak C., Ozcan C., Sahin T., Yilmaz G., Ozyuvali E., Sarikaya S., et al.* Risk Factors of Infectious Complications after Flexible Uretero-renoscopy with Laser Lithotripsy. Urol J. 2018;15(4):158-163. https://doi.org/10.22037/uj.v0i0.3967
16. *Mi Q., Meng X., Meng L., Chen D., Fang S.* Risk Factors for Systemic Inflammatory Response Syndrome Induced by Flexible Ureteroscope Combined with Holmium Laser Lithotripsy. Biomed Res Int. 2020;2020:6842479. https://doi.org/10.1155/2020/6842479
17. *Baseskioglu B.* The Prevalence of Urinary Tract Infection Following Flexible Ureterenoscopy and the Associated Risk Factors. Urol J. 2019;16(5):439-442. https://doi.org/10.22037/uj.v0i0.4340
18. *Ma Y.C., Jian Z.Y., Yuan C., Li H., Wang K.J.* Risk Factors of Infectious Complications after Ureteroscopy: A Systematic Review and Meta-Analysis Based on Adjusted Effect Estimate. Surg Infect (Larchmt). 2020;21(10):811-822. https://doi.org/10.1089/sur.2020.013
19. *Baboudjian M., Gondran-Tellier B., Abdallah R., Sichez P.C., Akiki A., Gaillet S., et al.* Predictive risk factors of urinary tract infection following flexible ureteroscopy despite preoperative precautions to avoid infectious complications. World J Urol. 2020;38(5):1253-1259. https://doi.org/10.1007/s00345-019-02891-8
20. *Bhojani N., Miller L.E., Bhattacharyya S., Cutone B., Chew B.H.* Risk Factors for Urosepsis After Ureteroscopy for Stone Disease: A Systematic Review with Meta-Analysis. J Endourol. 2021;35(7):991-1000. https://doi.org/10.1089/end.2020.1133
21. *Wang F., Hong Y., Yang Z., Ye L.* Comparison of retrograde intrarenal surgery and standard percutaneous nephrolithotomy for management of stones at ureteropelvic junction with high-grade hydronephrosis. Sci Rep. 2021;11(1):14050. https://doi.org/10.1038/s41598-021-93551-8
22. *Corrales M., Sierra A., Doizi S., Traxer O.* Risk of Sepsis in Retrograde Intrarenal Surgery: A Systematic Review of the Literature. Eur Urol Open Sci. 2022;44:84-91. https://doi.org/10.1016/j.euros.2022.08.008
23. *Zhong W., Leto G., Wang L., Zeng G.* Systemic inflammatory response syndrome after flexible ureteroscopic lithotripsy: a study of risk factors. J Endourol. 2015;29(1):25-28. https://doi.org/10.1089/end.2014.0409
24. *Loftus C.J., Hinck B., Makovey I., Sivalingam S., Monga M.* Mini Versus Standard Percutaneous Nephrolithotomy: The Impact of Sheath Size on Intrarenal Pelvic Pressure and Infectious Complications in a Porcine Model. J Endourol. 2018;32(4):350-353. https://doi.org/ 10.1089/end.2017.0602
25. *Omar M., Noble M., Sivalingam S., El Mahdy A., Gamal A., Farag M., et al.* Systemic Inflammatory Response Syndrome after Percutaneous Nephrolithotomy: A Randomized Single-Blind Clinical Trial Evaluating the Impact of Irrigation Pressure. J Urol. 2016;196(1):109-114. https://doi.org/10.1016/j.juro.2016.01.104
26. *Tokas T., Skolarikos A., Herrmann TR.W., Nagele U.;* Training and Research in Urological Surgery and Technology (T.R.U.S.T.)-Group. Pressure matters 2: intrarenal pressure ranges during upper-tract endourological procedures. World J Urol. 2019;37(1):133-142. https://doi.org/10.1007/s00345-018-2379-3.
27. *Jung H., Osther P.J.* Intraluminal pressure profiles during flexible

ureterorenoscopy. Springerplus. 2015;4:373. Doi: 10.1186/s40064-015-1114-4.
28. *Kottooran C., Twum-Ampofo J., Lee J., Saunders J., Franco M., Budrewicz J., et al.* Evaluation of fluid absorption during flexible ureteroscopy in an in vivo porcine model. BJU Int. 2023;131(2):213-218. https://doi.org/10.1111/bju.15858
29. *Sener T.E., Cloutier J., Villa L., Marson F., Butticè S., Doizi S., et al.* Can We Provide Low Intrarenal Pressures with Good Irrigation Flow by Decreasing the Size of Ureteral Access Sheaths? J Endourol. 2016;30(1):49-55. https://doi.org/10.1089/end.2015.0387
30. *Wright A., Williams K., Somani B., Rukin N.* Intrarenal pressure and irrigation flow with commonly used ureteric access sheaths and instruments. Cent European J Urol. 2015;68(4):434-438. https://doi.org/10.5173/ceju.2015.604.
31. *Auge B.K., Pietrow P.K., Lallas C.D., Raj G.V., Santa-Cruz R.W., Preminger G.M.* Ureteral access sheath provides protection against elevated renal pressures during routine flexible ureteroscopic stone manipulation. J Endourol. 2004;18(1):33-36. https://doi.org/10.1089/089277904322836631.
32. *Rehman J., Monga M., Landman J., Lee D.I., Felfela T., Conradie M.C., et al.* Characterization of intrapelvic pressure during ureteropyeloscopy with ureteral access sheaths. Urology. 2003;61(4):713-718. https://doi.org/10.1016/s0090-4295(02)02440-8
33. *Chen Y., Liao B., Feng S., Ye D., Zeng G., Wang K., et al.* Comparison of Safety and Efficacy in Preventing Postoperative Infectious Complications of a 14/16F Ureteral Access Sheath with a 12/14F Ureteral Access Sheath in Flexible Ureteroscopic Lithotripsy. J Endourol. 2018;32(10):923-927. https://doi.org/10.1089/end.2018.0222
34. *Traxer O., Wendt-Nordahl G., Sodha H., Rassweiler J., Meretyk S., Tefekli A., et al.* Differences in renal stone treatment and outcomes for patients treated either with or without the support of a ureteral access sheath: The Clinical Research Office of the Endourological Society Ureteroscopy Global Study. World J Urol. 2015;33(12):2137-2144. https://doi.org/10.1007/s00345-015-1582-8.
35. *Xu Y., Min Z., Wan S.P., Nie H., Duan G.* Complications of retrograde intrarenal surgery classified by the modified Clavien grading system. Urolithiasis. 2018;46(2):197-202. https://doi.org/10.1007/s00240-017-0961-6
36. *Nevo A., Mano R., Baniel J., Lifshitz D.A.* Ureteric stent dwelling time: a risk factor for post-ureteroscopy sepsis. BJU Int. 2017;120(1):117-122. https://doi.org/10.1111/bju.13796
37. *Geraghty R.M., Pietropaolo A., Villa L., Fitzpatrick J., Shaw M., Veeratterapillay R., et al.* Post-Ureteroscopy Infections Are Linked to Pre-Operative Stent Dwell Time over Two Months: Outcomes of Three European Endourology Centres. J Clin Med. 2022;11(2):310. https://doi.org/ 10.3390/jcm11020310
38. *Castellani D., Teoh J.Y., Pavia M.P., Pretore E., Dell'Atti L., Galosi A.B., et al.* Assessing the Optimal Urine Culture for Predicting Systemic Inflammatory Response Syndrome After Percutaneous Nephrolithotomy and Retrograde Intrarenal Surgery: Results from a Systematic Review and Meta-Analysis. J Endourol. 2022;36(2):158-168. https://doi.org/10.1089/end.2021.0386
39. *Geraghty R.M., Pietropaolo A., Villa L., Fitzpatrick J., Shaw M., Veeratterapillay R., et al.* Post-Ureteroscopy Infections Are Linked to Pre-Operative Stent Dwell Time over Two Months: Outcomes of Three European Endourology Centres. J Clin Med. 2022;11(2):310. https://doi.org/10.3390/jcm11020310
40. *Nevo A., Mano R., Baniel J., Lifshitz D.A.* Ureteric stent dwelling time: a risk factor for post-ureteroscopy sepsis. BJU Int. 2017l;120(1):117-122. https://doi.org/10.1111/bju.13796
41. *Deng T., Liu B., Duan X., Cai C., Zhao Z., Zhu W., et al.* Antibiotic prophylaxis in ureteroscopic lithotripsy: a systematic review and meta-analysis of comparative studies. BJU Int. 2018;122(1):29-39. https://doi.org/10.1111/bju.14101.
42. *Khusid J.A., Hordines J.C., Sadiq A.S., Atallah W.M., Gupta M.* Prevention and Management of Infectious Complications of Retrograde Intrarenal Surgery. Front Surg. 2021;8:718583. https://doi.org/ 10.3389/fsurg.2021.718583
43. *Zisman A., Badaan S., Kastin A., Kravtsov A., Amiel G.E., Mullerad M.* Tailoring Antibiotic Prophylaxis for Ureteroscopic Procedures Based on Local Resistance Profiles May Lead to Reduced Rates of Infections and Urosepsis. Urol Int. 2020;104(1-2):106-112. https://doi.org/10.1159/000503905
44. *Chiu P.K., Chan C.K., Ma W.K., To K.C., Cheung F.K., Yiu M.K.* Subcapsular hematoma after ureteroscopy and laser lithotripsy. J Endourol. 2013;27(9):1115-1119. https://doi.org/10.1089/end.2013.0128
45. *Bai J., Li C., Wang S., Liu J., Ye Z., Yu X., et al.* Subcapsular renal haematoma after holmium:yttrium-aluminum-garnet laser ureterolithotripsy. BJU Int. 2012;109(8):1230-1234. https://doi.org/10.1111/j.1464-410X.2011.10490.x
46. *Nazer A., Awwad A.A., Aljuhayman A., Alasker A., Bin Hamri S.* Stone fragments migration into subcapsular renal hematoma post flexible ureterorenoscopy (unique presentation). J Surg Case Rep. 2019;2019(5):rjz125. https://doi.org/10.1093/jscr/rjz125
47. *Whitehurst L.A., Somani B.K.* Perirenal Hematoma After Ureteroscopy: A Systematic Review. J Endourol. 2017;31(5):438-445. https://doi.org/10.1089/end.2016.0832
48. *Kao M-H., Wang C-C.* Risk factors for developing a perirenal hematoma after flexible ureteroscopic lithotripsy. Urological Science. 2016;27(3):166–170. https://doi.org/10.1016/j.urols.2015.09.003
49. *Lee M.S., Connors B.A., Agarwal D.K., Assmus M.A., Williams J.C.. Jr, Large T., et al.* Determining the threshold of acute renal parenchymal damage for intrarenal pressure during flexible ureteroscopy using an in vivo pig model. World J Urol. 2022;40(11):2675-2681. https://doi.org/10.1007/s00345-022-04154-5
50. *Delvecchio F.C., Auge B.K., Brizuela R.M., Weizer A.Z., Silverstein A.D., Lallas C.D., et al.* Assessment of stricture formation with the ureteral access sheath. Urology. 2003;61(3):518-522; discussion 522. https://doi.org/10.1016/s0090-4295(02)02433-0.
51. *Traxer O., Thomas A.* Prospective evaluation and classification of ureteral wall injuries resulting from insertion of a ureteral access sheath during retrograde intrarenal surgery. J Urol. 2013;189(2):580-584. https://doi.org/10.1016/j.juro.2012.08.197
52. *Jessen J.P., Breda A., Brehmer M., Liatsikos E.N., Millan Rodriguez F., et al.* International Collaboration in Endourology: Multicenter Evaluation of Prestenting for Ureterorenoscopy. J Endourol. 2016;30(3):268-273. https://doi.org/10.1089/end.2015.0109
53. *Sung L.H., Cho D.Y.* The role of preoperative ureteral stenting in retrograde intrarenal surgery in renal stone patients: a propensity score-matched study. Transl Androl Urol. 2020;9(2):276-283. https://doi.org/10.21037/tau.2020.03.09
54. *Stern K.L., Loftus C.J., Doizi S., Traxer O., Monga M.* A Prospective Study Analyzing the Association Between High-grade Ureteral Access Sheath Injuries and the Formation of Ureteral Strictures. Urology. 2019;128:38-41. https://doi.org/10.1016/j.urology.2019.02.032
55. *Aykanat C., Balci M., Senel C., Ozercan A.Y., Coser S., Aslan Y., et al.* The Impact of Ureteral Access Sheath Size on Perioperative Parameters and Postoperative Ureteral Stricture in Retrograde Intrarenal Surgery. J Endourol. 2022;36(8):1013-1017. https://doi.org/10.1089/end.2021.0751
56. *Chang X., Wang Y., Li J., Han Z.* Prestenting Versus Nonprestenting on the Outcomes of Flexible Ureteroscopy for Large Upper Urinary Stones: A Systematic Review and Meta-Analysis. Urol Int. 2021;105(7-8):560-567. https://doi.org/10.1159/000506652
57. *Fahmy O., Shsm H., Lee C., Khairul-Asri M.G.* Impact of Preoperative Stenting on the Outcome of Flexible Ureterorenoscopy for Upper Urinary Tract Urolithiasis: A Systematic Review and Meta-Analysis. Urol Int. 2022;106(7):679-687. https://doi.org/10.1159/000518160
58. *Law Y.X.T., Teoh J.Y.C., Castellani D., Lim E.J., Chan E.O.T., Wroclawski M., et al.* Role of pre-operative ureteral stent on outcomes of retrograde intra-renal surgery (RIRS): systematic review and meta-analysis of 3831 patients and comparison of Asian and non-Asian cohorts. World J Urol. 2022;40(6):1377-1389. https://doi.org/10.1007/s00345-022-03935-2
59. *Lim K.S., Lim Y.W., Yong D.Z.P., Hao Y., Ho H.S.S., Ng L.G., et al.* Two Weeks Too Long: Optimal Duration for Ureteral Prestenting and Its Physiologic Effects on the Ureter in a Yorkshire-Landrace Pig Model. J Endourol. 2019;33(4):325-330. https://doi.org/10.1089/end.2018.0872

Received 06.03.2023
Accepted 17.10.2023
Financing source: Absents

Information about authors

Malkhasyan V.A. – M.D.; Professor of the Department of Urology, Russian University of Medicine, Head of Urology Department №67, Botkin City Clinical Hospital Moscow, Russia; e-mail: vigenmalkhasyan@gmail.com. https://orcid.org/0000-0002-2993-884X

Martov A.G. – Corresponding member of the Russian Academy of Sciences, M.D., Professor, Head of the Department of Urology and Andrology of A.I. Burnazyan SRC FMBC, FMBA of Russia, senior researcher of the Medical Research and Educational Center of Lomonosov Moscow State University, Moscow, Russia; e-mail: martovalex@mail.ru. https://orcid.org/0000-0001-6324-6110

Gadzhiev N.K. – M.D., Deputy Director for the Medical part (Urology) of the High Medical Technologies Clinic named after N.I. Pirogov St. Petersburg State University, St. Petersburg, Russia. https://orcid.org/0000-0002-6255-0193

Sukhikh S.O. – Ph.D., urologist of Botkin City Clinical Hospital, Moscow, Russia; e-mail: docsukhikh@gmail.ru. https://orcid.org/0000-0002-3840-0259

Grigoryan B.L. – Resident of the Department of Urology, Russian University of Medicine, Moscow, Russia; e-mail: bagybaga97@gmail.com. https://orcid.org/0000-0002-7698-0653

Pushkar D.Yu. – Academician of the Russian Academy of Sciences, M.D.; Professor, Head of the Department of Urology of the Russian University of Medicine, Moscow, Russia. Head, Moscow Urological Centre, Botkin City Clinical Hospital, Moscow, Russia; e-mail: pushkardm@mail.ru. https://orcid.org/0000-0002-6096-5723