©TEAM OF AUTHORS, 2024

S.V. Kotov [1,2], N.D. Korochkin [1,2], A.V. Vasilyiev[2], M.M. Iritsyan [1,2]

RECURRENT VARICOCELE: CAUSES AND TREATMENT

[1] N.I. Pirogov Russian National Research Medical University of the Ministry of Health of the Russian Federation, Moscow, Russian Federation; [2] N.I. Pirogov First City hospital, Moscow, Russian Federation

Corresponding author: N.D. Korochkin – postgraduate of the Department of Urology and Andrology of Medical Faculty of N.I. Pirogov Russian National Research Medical University, urologist of First City hospital named after N.I. Pirogov, Moscow, Russian Federation; e-mail: nikoro4kin@yandex.ru

Introduction. Among the different options for varicocele surgery, microsurgical varicocelectomy demonstrates the best results, but a relapse is subsequently detected in 1–3% of cases. It was previously believed that the cause of recurrence lies in the presence of various sources of venous outflow from the testicle, but recent studies show that the collaterals of the gonadal vein are the main reason of recurrence.
Purpose of the study: to determine the leading cause of recurrence, to evaluate the effectiveness and optimal surgical tactics depending on the method of primary treatment.
Materials and methods. Surgical treatment of 74 patients with recurrent varicocele was performed for 5 years. Depending on the method of primary treatment, two groups were formed: 1 – relapse after non-microsurgical varicocelectomy (n=37), 2 – relapse after microsurgical varicocelectomy (n=37). Patients of the first group underwent microsurgical subinguinal varicocelectomy. Patients of the second group underwent endovascular surgery or redo microsurgical varicocelectomy.
Results. 1 group. Scrotal pain syndrome was relieved in 90% of cases (n=18). Among patients with complaints of infertility (n=8), natural pregnancy occurred in 57,1% (n=4). An improvement in sperm parameters was found among 18 (75%) patients with pathospermia. The US-recurrence rate was 5.4% (n=2), clinical manifestation revealed in 1 case (2,7%). Intraoperatively, preserved branches of the gonadal vein were detected in all cases.
2 group. Scrotal pain syndrome was relieved in 95,8% of cases (n=23). Among patients with complaints of infertility (n=11), natural pregnancy occurred in 27,3% (n=3). An improvement in sperm parameters was found among 14 (73,7%) patients with pathospermia. The US recurrence rate after repeated microsurgery was 13% (n=3), after endovascular intervention – 38.5% (n=5). Clinical manifestation and indications for reoperation were identified in one patient who underwent endovascular embolization. Other cases of the second recurrence were subclinical, no indications for surgical treatment were identified. Renospermatic reflux was determined in all cases of phlebographic recurrence confirmation. No patients with ileospermatic reflux, as well as May-Turner syndrome, were identified. In 8 cases of phlebography, there was no technical possibility to perform embolization; in 3 patients, recurrence was not confirmed. Always the intact gonadal vein branches were identified mainly in the immediate vicinity of the testicular artery, in case of repeated microsurgical operation. There were no cases of testicular atrophy or postoperative hydrocele in any of the groups.
Conclusion. Missing collaterals from the gonadal vein basin play a key role in the genesis of varicocele recurrence. When choosing a surgical treatment option for patients with recurrent varicocele, it is necessary to take into account the method of primary treatment. The main factor to minimize the recurrence risk is the obligatory using of microsurgical techniques and a thorough revision of the spermatic cord components during the primary operation.

K e y w o r d s: varicocele, microsurgical varicocelectomy, Marmar operation, male infertility

The authors declare that they have no conflicts of interest. For citation: Kotov S.V., Korochkin N.D., Vasilyiev A.V., Iritsyan M.M. Recurrent varicocele: causes and treatment. Urologiia. 2024;3:14-20. Doi: https://dx.doi.org/10.18565/urology.2024.3.14-20

Introduction. Many surgical treatment options for varicocele have been proposed, most of which are of purely historical significance due to the high rate of recurrence and complications. Microsurgical varicocelectomy can be considered the first-line treatment, but recurrence is detected in 1–3% of cases [1]. There is a point of view that the cause of recurrence is a variety of sources of venous outflow from the testicle, but recent studies show that only gonadal vein collaterals are of importance [2–5].

Aim. To determine the main cause of varicocele recurrence, as well as the efficiency and optimal surgical tactics depending on the method of primary treatment.

Materials and methods. In the University Clinic of Urology of the Pirogov Russian National Research Medical University, based on the Urology Department of the Pirogov City Clinical Hospital No. 1, a total 74 patients with recurrent varicocele were undergone to treatment from 2017 to 2022. Depending on the primary intervention, they were included into two groups.

The group 1 included 37 patients who underwent various types of non-microsurgical varicocelectomy (*table 1*) and had clinical and ultrasound evidences of varicocele recurrence (dilated veins of the spermatic cord with a change in their diameter in orthostasis and retrograde blood flow at rest and/or during the Valsalva maneuver).

The age of the patients ranged from 18 to 42 years; the median age was 28 years. Left-side varicocele was

determined in 33 (89.2%), bilateral varicocele was found in 4 (10.8%) patients. According to the WHO classification, varicocele of Grade I was found in 2 (5.4%), II in 22 (59.5%), III in 13 (35.1%) cases [2]. During ultrasound examination, the average vein diameter of the pampiniform plexus in supine position was 2.9±0.2 mm, in orthostasis 3.6±0.2 mm, the average velocity of retrograde blood flow at rest was 8.9±1.3 cm/s. In all cases a positive Valsalva test was detected with an average velocity of retrograde blood flow of 27.0±4.2 cm/s; the volume of the ipsilateral testicle averaged 13.3±0.9 cc. Pain syndrome was presented in 20 (55.6%) patients. Infertile marriage was detected in 7 (18.9%) cases. Pathospermia was determined in 24 (66.7%) patients. The median total sperm count in patients with oligozoospermia (n=6) was 24.1 million [6.7; 31.2], the median concentration was 9.0 million/ml [3; 10.5], the median proportion of progressively motile sperm in those with asthenozoospermia (n=17) was 17% [11; 26]; the median proportion of sperm with normal morphology among patients with teratozoospermia (n=19) was 2% [1; 3].

The group 2 (n=37) included patients with clinical and ultrasound evidence of varicocele recurrence after microsurgical varicocelectomy.

The age of patients in the group 2 ranged from 18 to 43 years; the median age was 27 years. Most of patients had left-side varicocele (n=35; 94.6%), while 2 patients (5.4%) who had previously undergone bilateral intervention, had a relapse on the right. According to the WHO classification, grade I varicocele was determined in 3 (8.1%), grade II in 18 (48.7%), and grade III in 16 (43.2%) patients.

During ultrasound examination, the average vein diameter of the pampiniform plexus in supine position was 3.3±0.8 mm, in orthostasis 3.9±0.8 mm, the average velocity of retrograde blood flow at rest was 13.6±3.3 cm/s. In all cases a positive Valsalva test was revealed with a retrograde blood flow velocity of 31.7±6.9 cm/s; the volume of the ipsilateral testicle averaged 14.2±1.1 cc. Pain syndrome was presented in 27 patients (73.0%). Infertile marriage was detected in 12 (32.4%) men. Pathospermia was detected in 23 (62.2%) patients. The median total sperm count in patients with oligozoospermia (n=10) was 18.0 million [10.2; 31.7], the median concentration was 10.0 million/ml [2.9; 13.5], the median proportion of progressively motile sperm in patients with asthenozoospermia (n=12) was 20% [15; 26], and the median proportion of sperm with normal morphology among those with teratozoospermia (n=15) was 1% [1; 3].

During 6–12 months after the intervention, a follow-up examination was performed, including taking history, a physical examination, ultrasound examination and ejaculate analysis.

The end points of the study were the pregnancy rate, the frequency of pain relief, changes in ejaculate, ultrasound features, and the rate of varicocele recurrence. In case of exclusively ultrasound signs of varicocele recurrence the term «ultrasound recurrence» was used. If the patient had indications for repeated intervention in addition to the ultrasound features, this condition was designated by the term «clinical recurrence».

The study was prospective. In case of recurrent varicocele after non-microsurgical interventions, patients underwent microsurgical subinguinal varicocelectomy as the most effective and safe treatment option. In patients with recurrent varicocele after microsurgical varicocelectomy, patients underwent retrograde phlebography, depending on the results of which a decision was made on the method of treatment, including embolization, repeated microsurgical varicocelectomy or dynamic follow-up, if there was no phlebographic features of recurrence. In addition, in 14 men, repeated microsurgical varicocelectomy was performed without previous endovascular intervention due to the patient's refusal.

Statistical analysis was done on a personal computer using Microsoft Excel, 2016, and IBM SPSS Statistics, 26. All obtained medical history, clinical, laboratory, and imaging data were entered into a Microsoft Excel database developed by the author and processed using descriptive statistics. Quantitative indicators were tested for the normal distribution using the Shapiro–Wilk test. Quantitative indicators that had a normal distribution were described using means (M) and standard deviations (SD), the boundaries of the 95% confidence interval (95% CI). In the absence of a normal distribution, quantitative data were described using the median (Me), lower and upper quartiles (Q1–Q3). Categorical data were described using absolute values and percentages. With a normal distribution of quantitative indicators for two independent samples, Student's t-test was used. Comparison of quantitative indicators that do not follow a normal distribution was performed using the Mann–Whitney U test.

Results. The method of choice of surgical treatment for patients in Group 1 was microsurgical subinguinal varicocelectomy. In all cases, intact branches of the internal testicular vein were identified and ligated. The median number of ligated veins was 7.5 [5; 9.5]. The average duration of surgery was 1 hour 15 minutes (from 40 minutes to 2 hours).

Scrotal pain syndrome persisted in two cases (10% of patients complaining of pain), and no signs of recurrence were found. Four (57.1%) of seven men with infertility

Table 1

Distribution of patients in group 1 depending on the type of primary procedure

Type of primary procedure	n	
	Abs.	%
Ivanissevich technique	23	62,2
Palomo procedure	2	5,4
Laparoscopic varicocelectomy	9	24,3
Embolization	3	8,1

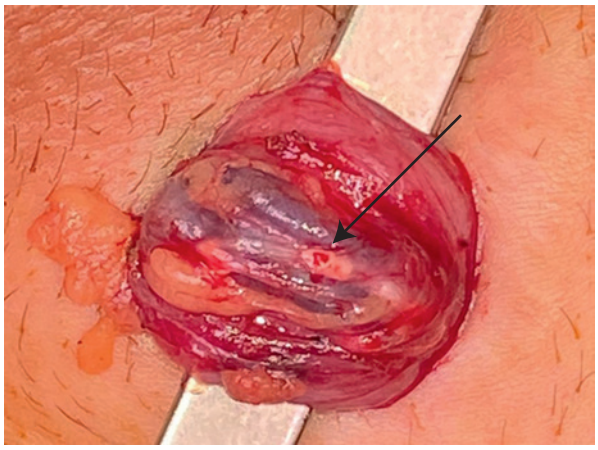

Figure. Residual veins of the pampiniform plexus. The arrow shows the stump of the vein ligated during the primary procedure

achieved natural conception. Among patients with pathospermia, improvement in ejaculate parameters was found in 18 (75%) cases. The median increase in the total sperm count in those with oligozoospermia was 36.7 [9.5; 41.4] million (p<0.05), the median increase in concentration was 7.5 [3.8; 10.5] million/ml (p<0.05). The proportion of progressively motile spermatozoa among patients with asthenozoospermia increased by 12% [7; 20] (p<0.05). The proportion of spermatozoa with normal morphology in patients with teratozoospermia increased by 1.0% [0.5; 1.0] (p<0.05). Ultrasound examination revealed a decrease in the average diameter of the veins of the pampiniform plexus in supine position to 2.2±0.5 mm (p<0.05), in orthostasis to 2.6±0.6 mm (p<0.05), an increase in the volume of the ipsilateral testicle to 15.1±2.7 cc (p<0.05).

There were no cases of postoperative hydrocele or testicular atrophy. The frequency of second ultrasound relapse was 5.4% (n=2) (*table 2*). In both cases, the primary procedure was the Ivanissevich technique. Indications for repeated surgical intervention were identified in one (2.7%) of them. He underwent embolization of the left testicular vein with an achievement of a clinical effect. However, ultrasound examination recorded retrograde blood flow and dilated veins of the pampiniform plexus. Despite the ultrasound recurrence, there were no indications for surgical treatment. Patients in the group 2 underwent microsurgical subinguinal varicocelectomy (n=14) or retrograde phlebography of the gonadal and iliac veins (n=23). Embolization was performed in 12 cases. In 8 (34.8%) patients, there was no technical possibility of embolization due to the structural features of the testicular vein; these men underwent repeated microsurgical varicocelectomy. In all cases of phlebographic verification of relapse (n=20), reflux from renal vein was detected. There were no patients with iliac reflux or May-Thurner syndrome. In 3 (13%) cases, relapse was not confirmed by phlebography; patients were excluded from the study. The average duration of the endovascular intervention was 50 min (from 25 min to 1 h 30 min). In all cases, patients were discharged the next day after the procedure.

As in the group 1, in all patients (n=22) during microsurgical varicocelectomy, the remaining branches of the internal testicular vein were identified and ligated (see the figure). The median number of ligated veins was 8 [4; 10]. The average time of repeated microsurgical varicocelectomy was 1 h 20 min (from 45 min to 2 h 20 min). Patients were treated in a short-stay hospital and discharged for outpatient treatment on the same day.

One patient had scrotal pain (4.2% of those complaining of pain). Three (27.3%) patients out of 11 with infertility achieved natural conception. Improvement of ejaculate parameters was noted in 14 (73.7%) men with pathospermia. The median increase in the total sperm count in patients with oligozoospermia was 25.6 [14.6; 34.3] million (p<0.05), the median elevation of concentration was 5.5 [4.3; 7.6] million/ml. The median increase in the proportion of progressively motile sperm among those with asthenozoospermia was 15% [4; 18] (p<0.05). The median increase in the proportion of sperm with normal morphology in patients with initial teratozoospermia was 1.0% [0.0; 1.0] (p<0.05). Ultrasound examination revealed a decrease in the average diameter of the veins of the pampiniform plexus in supine position to 2.4±0.7 (p<0.05), in orthostasis to 2.7±0.7 mm (p<0.05), an increase in the volume of the testicle to 15.8±3.1 cc (p<0.05).

No cases of testicular atrophy or postoperative hydrocele were found. In 8 patients in the group 2, ultrasound signs of relapse persisted (dilation of the veins of the pampiniform plexus by more than 3 mm in combination with retrograde blood flow for more than 2 s) (see *table 2*), including 4 patients after embolization of gonadal vein. Two men underwent diagnostic phlebography followed by repeated microsurgical varicocelectomy. One patient underwent embolization and then microsurgical varicocelectomy. It should be noted that, despite the ultrasound evidence for varicocele recurrence, all these patients achieved a clinical effect and there were no indications for repeated treatment.

Discussion. The main collector of venous blood from the testicle is the internal gonadal vein, which can be represented by various anatomical variants. It was demonstrated in the studies of Bahren and Murray and served as the basis for respective classifications [7, 8]. In

Table 2

Varicocele recurrence rate

Group	Method of retreatment	n	Rate of second recurrence based on ultrasound, %	Rate of second clinical recurrence, %
1	Microsurgical varicocelectomy	37	5.3 (n=2)	2.7 (n=1)
2	Embolization	13	38.5 (n=5)	7.7 (n=1)
	Microsurgical varicocelectomy	23	13.0 (n=3)	0

addition, the testicle has a developed system of venous collaterals, including the vein of the vas deferens, the cremasteric vein, the external genital vein, transscrotal collaterals and gubernaculum veins [9].

A key issue in understanding the true genesis of recurrence is the possibility of reflux through the veins of the vas deferens and the cremaster muscle [10]. In our study, 23 patients with retrograde blood flow detected by ultrasound examination underwent retrograde phlebography of the testicular and iliac veins, and in all 20 cases where relapse was verified, reflux into the pampiniform plexus occurred exclusively through the gonadal vein.

In turn, there were no patients with reflux from the iliac vein system, which doubts on the possibility of significant reflux through the veins of the vas deferens and the cremaster muscle.

Similar results were obtained in a number of phlebographic studies performed at the end of the 20th century [2–4]. Having studied the anatomy of the venous plexus in patients with and without varicocele, Wishany argues that venous outflow occurs primarily through the gonadal vein, as well as the external genital vein, while the cremasteric collaterals and the veins of the vas deferens are of secondary importance [2].

In 1999, Franco et al. [3] published the results of phlebography of 73 patients with varicocele, 19 of whom had a relapse. The authors concluded that the gonadal vein plays a leading role in the recurrence, while the remaining venous collaterals dilate due to hemodynamic overload as a result of reflux in the main vessel. Thus, the question was raised about the necessity of routine ligation of these veins [4]. Fifteen years later, in a study of 33 patients with recurrent varicocele after laparoscopic and microsurgical procedures, the same conclusions were made [5].

Among domestic articles, the thesis of A.S. Sidnev «Laparoscopic treatment of recurrent varicocele in children» was devoted to this problem. The authors compared endovascular and laparoscopic treatment options. There was no reflux from iliac vein in any case, «which confirms the exceptional role of renal-testicular venous reflux in the development of varicocele».

The obtained results, as well as published data, allow to conclude that the cause of varicocele recurrence are collaterals of the testicular vein. On the other hand, there is an opinion about the role of gubernacular veins. Goldstein's study showed that delivery of the testicle into the wound and ligation of the gubernaculum veins reduces the recurrence rate to 0.6% [11]. However, when directly comparing microsurgical varicocelectomy with and without testicular delivery, no significant differences were found in either the results or the recurrence rate [12].

It is also worth noting that recurrence of varicocele may be associated with systemic disorders, such as undifferentiated connective tissue disease [13, 14]. An association of recurrence with May-Thurner syndrome, which is associated with compression of the left common iliac vein between the right common iliac artery and the spine, is also possible [15, 16].

Recurrence after Ivanissevich and Palomo procedures, laparoscopic and endovascular interventions is associated with the presence of additional branches of the testicular vein at the retroperitoneal and inguinal levels. These branches can anastomose with either the main gonadal vein, renal vein or inferior vena cava. Cross-communicating veins between the right and left testicular veins have also been described [17]. For these reasons, microsurgical subinguinal varicocelectomy can be considered the method of choice in case of recurrence after non-microsurgical interventions.

The fundamental issue in our study was recurrence after microsurgical varicocelectomy. On the one hand, the recurrence rate is minimal compared to other treatment options, on the other hand, this method does not guarantee a completely absence of recurrence. According to a systematic review, a rate of recurrences reaches 3.57% [18].

In our study, the overall rate of second ultrasound recurrence after microsurgical varicocelectomy was 8.3% (5.3% vs. 13.0% in Group 1 and Group 2, respectively). It is noteworthy that the rate of recurrence was higher in Group 2. Retrograde embolization in this group demonstrated the worst result, which consisted of 38.5% of second recurrences, and in a third of the cases it was not performed due to anatomical features. On the other hand, the rate of clinical recurrence did not differ between the groups.

According to a systematic review [19], the rate of second recurrence after open, laparoscopic and endovascular procedures was 3.8%, 17.6% and 3.3%, respectively. When comparing open techniques, the rate of recurrence for microsurgical varicocelectomy was significantly lower (0.6%) than for non- microsurgical (19%). Microsurgical varicocelectomy demonstrates good long-term results, including an increase in sperm concentration and natural pregnancy rate, which depend, among other, on the method of primary treatment [20, 21]. In our study, significant improvement of ejaculate parameters was achieved in 73–75% of patients with initial pathospermia, including an increase in the total number of spermatozoa (group 1 by 36.7 million, group 2 by 25.6), sperm concentration (by 7.5 and 5.5 million/ml, respectively), the proportion of progressively motile forms (by 12 and 15%, respectively), and the proportion of morphologically normal forms (by 1% in both groups). In a systematic review comparing different treatment methods for patients with recurrent varicocele, improvement in sperm parameters was achieved in 77.5% of cases with surgical treatment (open/laparoscopic/microsurgical) and in 62.5% with endovascular procedures [19]. In our study, no significant differences in the improvement of sperm parameters were found between the embolization and microsurgical varicocelectomy. On the other hand, the improvement in sperm parameters was comparable to the results of varicocelectomy for primary varicocele [22]. In the meta-analysis, the average improvement in the proportion of progressively motile forms was 9.69% (95% CI: 4.86–14.52), while the sperm concentration increased by 12.3 million/ml (95% CI: 9.45–15.19).

In the group 1, the pregnancy rate was significantly higher (57.1 vs. 27.3% in the group 2). Among primary procedures, microsurgical varicocelectomy demonstrates the highest pregnancy rate of 41.9% [22]. In the meta-analysis performed by Marmar et al. [23], pregnancy after surgical treatment developed in 33% of cases. A systematic review [19] showed that after treatment of recurrent varicocele, the pregnancy rate was higher with surgical (44.3%) than with endovascular (17.9%)

procedures. The pain relief rate in our study was 90% in the group 1 and 95.8% in the group 2. According to the literature [24, 25], varicocelectomy leads to pain relief in 88% of cases. However, there is a lack of randomized studies evaluating the efficiency of varicocelectomy for orchalgia [20].

Recurrence after Marmar procedure is also caused by branches of the gonadal vein, so the use of microsurgical techniques and careful revision of all elements of the spermatic cord remain extremely important factors. In particular, unligated veins around branches of the testicular artery are most often detected during reoperation. An important aspect is the correct performance of ultrasonography of the scrotum, which allows avoiding overdiagnosis of recurrence [26]. During reoperation, the surgeon has to dissect abnormal tissues, and in some cases, it is difficult to identify the structures of the spermatic cord, which is associated with an increased risk of complications due to injury to the testicular artery and lymphatic vessels. The endovascular approach allows to overcome these difficulties, but is inferior to the microsurgical technique in terms of postoperative results, recurrence rate, and is not always technically feasible [27]. The failure rate of phlebography after varicocelectomy is 15–22% [28, 29]. The main reasons for technical failure in phlebography are anatomical variations, as well as vasospasm during an attempt to catheterize the vessel [29]. As a consequence, the choice of method will depend on many factors, including the experience of the surgeon, the technical equipment of the clinic, and the patient's desire.

Conclusion. Missed collaterals from the gonadal vein play a key role in the varicocele recurrence. The choice of surgical treatment option for patients with recurrence should be determined by the primary treatment method. In case of recurrence after non-microsurgical varicocelectomy options, microsurgical surgery via inguinal or subinguinal approach is preferable. In case of recurrence after microsurgical surgery, various treatment options and their combinations can be used. The fundamental factors for minimizing the risk of recurrence are the mandatory use of microsurgical technique and careful revision of the spermatic cord components during the primary procedure.

REFERENCES

1. *Ahvlediani N.D., Reva I.A., Chernushenko A.S.* Varicocele: role in the development of male infertility and surgical treatment techniques. Urologiia. 2020;4;111–118. Russian (Ахвледиани Н.Д., Рева И.А., Чернушенко А.С. Варикоцеле: роль в развитии мужского бесплодия и методики хирургического лечения. Урология. 2020;4;111–118). Doi: 10.18565/urology.2020.4.111-118.
2. *Wishahi M.M.* Anatomy of the spermatic venous plexus (pampiniform plexus) in men with and without varicocele: intraoperative venographic study. J Urol. 1992;147(5):1285–1289. Doi: 10.1016/s0022-5347(17)37544-4. PMID: 1569670.
3. *Franco G., Iori F., de Dominicis C., Dal Forno S., Mander A., Laurenti C.* Challenging the role of cremasteric reflux in the pathogenesis of varicocele using a new venographic approach. J Urol. 1999;161(1):117–121. PMID: 10037382.
4. *Franco G., Leonardo C.* Is selective internal spermatic venography necessary in detecting recurrent varicocele after surgical repair? Eur Urol. 2002;42(2):192–193. Doi: 10.1016/s0302-2838(02)00262-2.
5. *Jargiello T., Drelich-Zbroja A., Falkowski A., Sojka M., Pyra K., Szczerbo-Trojanowska M.* Endovascular transcatheter embolization of recurrent postsurgical varicocele: anatomic reasons for surgical failure. Acta Radiologica. 2015;56(1):63–69. Doi: 10.1177/0284185113519624.
6. WHO Manual for the Standardized Investigation and Diagnosis of the Infertile Couple. 2000, Cambridge University Press: Cambridge. https://www.who.int/reproductivehealth/publications/infertility/9780521431361/en/
7. *Bahren W., Lenz M., Porst H., Wierschin W.* Side-effects, complications and contra-indications of percutaneous sclerotherapy of the internal spermatic vein for the treatment of idiopathic varicoceles. Fortschr Rontgenstr. 1983;138:172–179. Doi: 10.1055/s-2008-1055705.
8. *Murray R.R. Jr, Mitchell S.E., Kadir S., Kaufman S.L., Chang R., Kinnison M.L., Smyth J.W., White R.I. Jr.* Comparison of recurrent varicocele anatomy following surgery and percutaneous balloon occlusion. J Urol. 1986;135(2):286–289. Doi: 10.1016/s0022-5347(17)45615-1.
9. *Wein A.J., Kavoussi L.R., Partin A.W., Peters C.A.* Campbell-Walsh Urology. 11th ed. Philadelphia: Saunders. 2016;4168.
10. *Coolsaet B.L.* The varicocele syndrome: venography determining the optimal level for surgical management. J Urol. 1980;124(6):833–839. Doi: 10.1016/s0022-5347(17)55688-8. PMID: 7441834.
11. *Goldstein M., Gilbert B.R., Dicker A.P., Dwosh J., Gnecco C.* Microsurgical inguinal varicocelectomy with delivery of the testis: an artery and lymphatic sparing technique. J Urol. 1992;148(6):1808–1811. Doi: 10.1016/s0022-5347(17)37035-0. PMID: 1433614.
12. *Ramasamy R., Schlegel P.N.* Microsurgical inguinal varicocelectomy with and without testicular delivery. Urology. 2006;68:1323–1326. Doi: 10.1016/j.urology.2006.08.1113.
13. *Kadurina T.I.* Hereditary collagenopathies: clinical presentation, diagnosis, treatment and follow-up. SPb.: Nevskii dialekt, 2000;270 p. Russian (Кадурина Т.И. Наследственные коллагенопатии: клиника, диагностика, лечение, диспансеризация. СПб.: Невский диалект, 2000;270 с.).
14. *Studennikova V.V., Severgina L.O., Ismailov M.T.* Current view on the varicocele pathogenesis and the problem of the development of its relapses. Urologiia. 2018;1;150-154. Russian (Студенникова В.В., Севергина Л.О., Исмаилов М.Т. Современный взгляд на патогенез варикоцеле и проблему развития его рецидивов. Урология. 2018;1;150–154). Doi 10.18565/urology.2018.1.150-154.
15. *Zhukov O.B., Ukolov V.A., Babushkina E.V., Evdokimov V.V.* Recurrent varicocele and May-Thurner syndrome. Urology Herald. 2018;6(3):17–25. Russian (Жуков О.Б., Уколов В.А., Бабушкина Е.В., Евдокимов В.В. Рецидивирующее варикоцеле и синдром May-Thurner. Вестник урологии. 2018;6(3):17–25). https://doi.org/10.21886/2308-6424-2018-6-3-17-25
16. *Kapto A.A.* May-Thurner syndrome and varicose veins of the pelvic organs in men. Andrology and Genital Surgery. 2018;19(4):28-38. Russian (Капто А.А. Синдроя Мея-Тернера и варикозная болезнь вен органов малого таза у мужчин. Андрология и гентиальная хирургия. 2018;19(4):28-38). https://doi.org/10.17650/2070-9781-2018-19-4-28-38
17. *Halpern J, Mittal S, Pereira K, Bhatia S, Ramasamy R.* Percutaneous embolization of varicocele: technique, indications, relative contraindications, and complications. Asian J Androl. 2016;18(2):234-8. doi: 10.4103/1008-682X.169985. PMID: 26658060; PMCID: PMC4770492.
18. *Rotker K, Sigman M.* Recurrent varicocele. Asian J Androl. 2016;18(2):229-33. doi: 10.4103/1008-682X.171578. PMID: 26806078; PMCID: PMC4770491.
19. *Çayan S, Orhan İ, Akbay E, Kadıoğlu A.* Systematic review of treatment methods for recurrent varicoceles to compare post-treatment sperm parameters, pregnancy and complication rates. Andrologia. 2019;51(11):e13419. doi:10.1111/and.13419
20. *Olefir Yu.V., Efremov E.A., Rodionov M.A., Zhivulko A.R., Popov D.M., Monakov D.M., Faniev M.V.* Clinical significance of varicocelectomy: literature review. Andrology and Genital Surgery. 2023;24(2):49-57. Russian (Олефир Ю.В., Ефремов Е.А., Родионов М.А., Живулько А.Р., Попов Д.М., Монаков Д.М., Фаниев М.В. Клиническое значение варикоцелэктомии: обзор литературы. Андрология и генитальная хирургия. 2023;24(2):49-57). https://doi.org/10.17650/2070-9781-2023-24-2-49-57
21. *Gamidov S.I., Shatylko T.V., Bicoev T.B., Gasanov N.G., Mammaev*

R.U. Reproductive function in men with recurrent varicocele. Akusherstvo i Ginekologiya 2020;4:176-181. Russian (Гамидов С.И., Шатылко Т.В., Бицоев Т.Б., Гасанов Н.Г., Маммаев Р.У. Репродуктивная функция у мужчин с рецидивами варикоцеле. Акушерство и гинекология. 2020;4:176-181). https://dx.doi.org/10.18565/aig.2020.4.176-181
22. *Baazeem A, Belzile E, Ciampi A, Dohle G, Jarvi K, Salonia A, Weidner W, Zini A.* Varicocele and male factor infertility treatment: a new meta-analysis and review of the role of varicocele repair. Eur Urol. 2011;60(4):796-808. doi: 10.1016/j.eururo.2011.06.018.
23. *Marmar JL, Agarwal A, Prabakaran S, Agarwal R, Short RA, Benoff S, Thomas AJ Jr.* Reassessing the value of varicocelectomy as a treatment for male subfertility with a new meta-analysis. Fertil Steril. 2007;88(3):639-48. doi: 10.1016/j.fertnstert.2006.12.008. Epub 2007 Apr 16. PMID: 17434508.
24. *Elzanaty S, Johansen CE.* Microsurgical Varicocele Repair on Men with Grade III Lesions and Chronic Dull Scrotal Pain: A Pilot Study. Curr Urol. 2015;8(1):29-31. doi: 10.1159/000365685.
25. *Yaman O, Ozdiler E, Anafarta K, Göğüş O.* Effect of microsurgical subinguinal varicocele ligation to treat pain. Urology. 2000;55(1):107-8. doi: 10.1016/s0090-4295(99)00374-x. PMID: 10654904.
26. *Gamidov S.I., Druzhinina N.K., Shatylko T.V., Popova A.Yu., Safiullin R.I.* Technical aspects of ultrasound diagnostics of varicocele and analysis of European clinical guidelines. Experimental and Clinical Urology. 2022;15(3)102-108; Russian (Гамидов С.И., Дружинина Н.К., Шатылко Т.В., Попова А.Ю., Сафиуллин Р.И. Технические аспекты ультразвуковой диагностики варикоцеле и анализ европейских клинических рекомендаций. Экспериментальная и клиническая Урология. 2022;15(3)102-108). https://doi.org/10.29188/2222-8543-2022-15-3-102-108)
27. *Kotov S.V., Korochkin N.D., Klimenko A.A.* Recurrent varicocele. Urology Herald. 2021;9(2):132-141. Russian (Котов С.В., Корочкин Н.Д., Клименко А.А. Рецидивное варикоцеле. Вестник урологии. 2021;9(2):132-141). https://doi.org/10.21886/2308-6424-2021-9-2-132-141
28. *Punekar SV, Prem AR, Ridhorkar VR, Deshmukh HL, Kelkar AR.* Post-surgical recurrent varicocele: efficacy of internal spermatic venography and steel-coil embolization. Br J Urol. 1996;77(1):124–28. Doi: 10.1046/j.1464-410x.1996.82321.x. PMID: 8653282.
29. *Feneley M.R., Pal M.K., Nockler I.B., Hendry W.F.* Retrograde embolization and causes of failure in the primary treatment of varicocele. Br J Urol. 1997;80(4):642–646. Doi: 10.1046/j.1464-410x.1997.00407.x. PMID: 9352706.

Received 14.04.2024
Accepted 30.04.2024
Financing. Authors declare no conflict of interest.

Authors' contributions: Kotov S.V. – concept and design of the study, 25%. Korochkin N.D. – material collection and statistical processing, text writing, 25%. Vasilyiev A.V. – material collection and statistical processing, 25%. Iritsyan M.M. – material collection and statistical processing, text correction, 25%.

Information about authors:

Kotov S.V. – Dr.Sc., Head of the Department of Urology and Andrology, N.I. Pirogov Russian National Research Medical University, Head of the University Urology Clinic of N.I. Pirogov RNRMU, Moscow, Russia; e-mail: urokotov@mail.ru. ORCID iD 0000-0003-3764-6131

Korochkin N.D. – postgraduate of the Department of Urology and Andrology of Medical Faculty of N.I. Pirogov Russian National Research Medical University, urologist of First City hospital named after N.I. Pirogov, Moscow, Russia; e-mail: nikoro4kin@yandex.ru. ORCID iD 0000-0002-9075-2948

Vasilyiev A.V. – head of the Department of X-ray surgical methods of diagnosis and treatment №2 of First City hospital named after N.I. Pirogov, Moscow, Russia; e-mail: drvasilevav@mail.ru. ORCID iD 0000-0002-3881-6107

Iritsyan M.M. – PhD, assistant of the Department of Urology and Andrology of Medical Faculty of N.I. Pirogov Russian National Research Medical University, urologist of First City hospital named after N.I. Pirogov, Moscow, Russia; e-mail: misha-res@yandex.ru. ORCID iD 0000-0002-6271-0556