©TEAM OF AUTHORS, 2025

M.D. Trishkin[1], E.V. Shpot[1], Ya.N. Chernov[1], D.V. Chinenov[1], A.Yu. Votyakov[1], H.A. Hizriev[1], X.A. Astakhova[2], I.N. Kurepta[2], E.A. Smirnova[2], A.G. Smoleevskiy1, P.V. Glybochko[1]

EARLY EVALUATION OF THE EFFICACY OF RADIOGUIDED SURGERY IN REDUCING THE INCIDENCE OF LYMPHOCELE AND LOWER LIMB LYMPHEDEMA AFTER ROBOT-ASSISTED PROSTATECTOMY WITH PELVIC LYMPH NODE DISSECTION

[1]Institute of Urology and Human Reproductive Health of the I.M. Sechenov First Moscow State Medical University Ministry of Health of the Russian Federation (Sechenov University), Moscow, Russia;
[2]N.V. Sklifosovskiy Institute of Clinical Medicine of the I.M. Sechenov First Moscow State Medical University Ministry of Health of the Russian Federation (Sechenov University), Moscow, Russia

Corresponding author: M.D. Trishkin – Ph.D. student, Institute of Urology and Human Reproductive Health of the I.M. Sechenov First Moscow State Medical University Ministry of Health of the Russian Federation (Sechenov University), Moscow, Russia, e-mail: maxtrishkin@bk.ru

Introduction. Robot-assisted radical prostatectomy (RARP) with pelvic lymphadenectomy (PLND) is the «gold standard» for the surgical treatment of prostate cancer with the risk of lymphatic involvement ⩾5% according to predictive nomograms. PLND is associated with the development of lymphatic complications (lymphocele, lymphedema) with a frequency up to 51%.
Aim. To evaluate the effectiveness of intraoperative navigation technique via a gamma probe and lymphotropic tracer (99mTc) during RARP with PLND to prevent the incidence of postoperative lymphatic complications.
Materials and methods. A single-center prospective study conducted between 2024 to 2025. The study included 50 patients with intermediate and high oncological risk according to the D'Amico classification. In the main group (n=23), RARP with PLND were performed with preservation of the lymphatic ducts of the lower limbs (LL). In the control group (n=27) RARP with PLND without LL lymphatic ducts preservation were performed. The frequency of the postoperative lymphatic complications was the primary endpoint, an evaluation of the intraoperative and postoperative complications was the secondary endpoint.
Results. Two patients in the main group developed lymphocele, which subsequently resolved within three months, compared with eight lymphoceles in the control group, one of which required repeat surgery. Lymphedema developed in one patient in the main group, compared with three patients in the control group. Intraoperative and postoperative parameters in the study group were comparable to those in the control group.
Conclusions. The use of radioguided surgery with lymphotropic tracer (99mTc) during RARP with PLND can reduce the risk of complications associated with the operation. The approach described above may be a promising solution to the problem of postoperative lymphatic complications.

Keywords: *prostate cancer, complications of pelvic lymphadenectomy, lymphocele, lower limb lymphedema, robot-assisted radical prostatectomy, gamma-probe*

The authors declare no conflict of interest. For citation: Trishkin M.D., Shpot E.V., Chernov Ya.N., Chinenov D.V., Votyakov A.Yu., Hizriev H.A., Astakhova X.A., Kurepta I.N., Smirnova E.A., Smoleevskiy A.G., Glybochko P.V. Early evaluation of the efficacy of radioguided surgery in reducing the incidence of lymphocele and lower limb lymphedema after robot-assisted prostatectomy with pelvic lymph node dissection. Urologiia. 2025;6:47-56.
Doi: https://dx.doi.org/10.18565/urology.2025.6.47-56

Introduction. Prostate cancer (PCa) is one of the most common malignancies in men. According to global statistics, PCa ranks second in incidence among oncourological diseases and fifth in cancer-specific mortality [1, 2]. In the Russian Federation, the past decade has been characterized by a heterogeneous pattern in PCa incidence and mortality rates. A marked decline in 2020 during the COVID-19 pandemic was associated with a temporary deterioration in the epidemiological situation and restrictive measures [3]. These measures led to reduced healthcare-seeking behavior and, consequently, to a decrease in PCa detection rates. At present, the indicators show an upward trend, driven by optimization of outpatient services, implementation of screening methods, advances in diagnostic technologies, and wider adoption of preventive measures [4]. Despite advances in early diagnosis, surgery remains the gold standard for the treatment of localized and locally advanced PCa [5].

In contemporary urological practice, preference is given to endoscopic video-assisted surgical techniques, in particular robot-assisted radical prostatectomy (RARP). The advantages of RARP include a lower risk of intraoperative and postoperative complications, high therapeutic efficacy, and improved early functional outcomes [6, 7]. Extended pelvic lymph node dissection (ePLND) is often performed during the procedure. According to the Clinical Guidelines of the Ministry of Health of the Russian Federation, ePLND is indicated in patients with a risk of lymphatic invasion of ⩾5% [8]. Despite ongoing debate regarding the oncological significance of ePLND [9, 10], this procedure remains the most reliable method for assessing the status of regional lymph nodes (LNs) and plays a key role in disease staging [11], given the limited sensitivity of currently available imaging modalities, including magnetic resonance imaging (MRI), computed tomography (CT), and posi-

tron emission tomography/computed tomography (PET/CT), for the detection of micrometastases [12].

The increasing incidence of PCa leads to a growing number of patients undergoing radical prostatectomy with pelvic lymph node dissection (PLND). Frequent complications of extended PLND include lymphocele formation and secondary lower limb lymphedema, which develop as a result of impaired regional lymphatic drainage [13]. In view of these possible postoperative consequences, preservation of the lower limb lymphatic collectors is an important issue as a potential strategy for preventing complications of extended PLND. During a search of the PubMed biomedical database, we identified a study aimed at developing a multispectral fluorescence imaging method for differentiating LNs draining the prostate from LNs draining the lower limbs [14]. The main limitation of that study was its preclinical nature, which did not allow reliable extrapolation of the findings to human anatomy and disease progression. An alternative approach to intraoperative guidance is radioguided surgery, based on the use of radionuclides followed by detection of their accumulation with a gamma probe. The most extensively studied and most commonly used radiopharmaceutical is ^{99m}Tc. This technique has high sensitivity for identifying sentinel LNs associated with the primary tumor [15–17]. No studies were found in the literature evaluating the possibility of using radioguided technologies for intraoperative identification of lower limb lymphatic collectors within the PLND field in order to reduce the incidence of postoperative complications.

Aim. To evaluate the efficiency of an intraoperative navigation technique using a gamma probe and a lymphotropic tracer (^{99m}Tc) during RARP and ePLND for reducing the incidence of postoperative lymphatic complications.

Materials and methods. A single-center prospective study was crried put at the Institute of Urology and Human Reproductive Health, Sechenov University, from July 2024 to May 2025. The study included 50 patients divided into two groups: the study group: RARP and ePLND with preservation of lower limb lymphatic collectors (LLLCs) (n=23), while in the control group RARP and ePLND without preservation of LLLCs was done (n=27). The study was approved by the local ethics committee (No. 30 dated September 29, 2023). Inclusion criterion: patients scheduled for RARP with ePLND with a calculated risk of regional LNs metastases of ⩾5% according to the Memorial Sloan Kettering Cancer Center (MSKCC), Briganti, and Russian Society of Oncourology nomograms. Exclusion criterion: developmental abnormalities of the lower limb lymphatic system identified on lymphoscintigraphy.

Methods for postoperative monitoring of lymphatic complications. To assess lymphocele formation, pelvic ultrasonography was performed on postoperative days 1, 7, and 90. Lower limb status was assessed by measuring circumferences at four points on each leg (*Fig. 1*). For these measurements, the patient was placed in a sitting position with the legs flexed at 90 degrees. The patella served as the anatomical landmark. Measurement of the circumference of the upper half of the lower limb was performed 10 cm above the superior border of the patella (first measurement point) and 15 cm distally from that point (second point). An analogous procedure was performed for the lower half of the lower limb, starting 10 cm below the inferior border of the patella. Leg circumference measurements were recorded in centimeters. The truncated cone formula was used to calculate the volume of the proximal and distal parts of the leg (mL). The estimated lower limb volume was calculated as the sum of these two values.

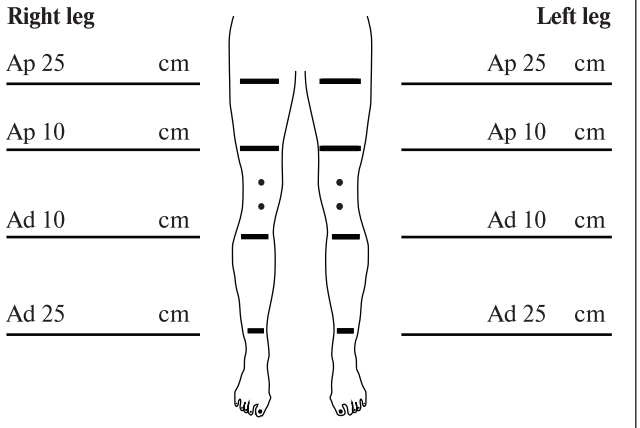

Note. Ap 25 – measurement of the circumference of the upper limb segment at a distance of 25 cm above the superior border of the patella; Ap 10 – measurement of the circumference of the upper limb segment at a distance of 10 cm above the superior border of the patella; Ad 10 – measurement of the circumference of the lower limb segment at a distance of 10 cm below the inferior border of the patella; Ad 25 – measurement of the circumference of the lower limb segment at a distance of 25 cm below the inferior border of the patella.

Fig. 1. Lower limb measurement scheme

$$V = \frac{h \times (C_1^2 + C_1 \times C_2 + C_2^2)}{12\pi}$$

V, lower limb volume, h, cone height (constant of 15 cm), C1, proximal measurement, C2, distal measurement.

Patients underwent lower limb lymphoscintigraphy with single-photon emission computed tomography/computed tomography (SPECT/CT) of the pelvic organs using a radiopharmaceutical labeled with ^{99m}Tc at a dose of 50 MBq for each leg, administered intradermally (effective dose 0.2+3.3 mSv), on the day before surgery to assess preservation of lymphatic transport function and to exclude lymphatic block and reflux. The injection site was the first interdigital space of the feet. On the day of surgery, 120 minutes before the procedure, the radiopharmaceutical was administered again.

Patients underwent lower limb lymphoscintigraphy with single-photon emission computed tomography/computed tomography (SPECT/CT) of the pelvic organs using a radiopharmaceutical labeled with ^{99m}Tc at a dose of 50 MBq for each leg, administered intradermally (effective dose 0.2+3.3 mSv), on the day before surgery to assess preservation of lymphatic transport function and to exclude lymphatic block and reflux. The injection site was the first interdigital space of the feet. On the day of surgery, 120 minutes before the procedure, the radiopharmaceutical was administered again.

Surgical technique. All procedures were performed through a transperitoneal approach using the Da Vinci Xi robotic surgical system (Intuitive Surgical, United States). Radioguidance was carried out using a rigid laparoscopic gamma probe (Amplitude Research and Technology Center LLC, Russia) connected to a portable personal computer with Radikal software (Amplitude Research

and Technology Center LLC, Russia). The sterile gamma probe was introduced into the abdominal cavity through a 12-mm port located above the right iliac crest. Real-time feedback on ^{99m}Tc activity measurements was provided by the portable personal computer with digital display and acoustic guidance. Background measurements on the transversus abdominis muscle served as the reference. In addition, radioactivity signals from structures located near the lower limb lymphatic collectors, including the ureters and iliac vessels, were measured to assess possible nonspecific uptake of the radioactive signal. Imaging results were considered positive if the activity of the radioactive tracer in the examined tissues exceeded the reference background value by 1.5 times. After verification of the lower limb lymphatic collectors, lymph node dissection was performed with preservation of these structures.

During ePLND, fibrofatty tissue with LNs located between the external and internal iliac vessels was removed from the level of the bifurcation of the common iliac artery to the artery encircling the pubic bone (a branch of the obturator artery). The lateral boundary of the lymph node dissection was the genitofemoral nerve, the medial boundary was the obturator nerve, and the posterior boundary was the obturator muscle. After pelvic lymph node removal, RARP was performed.

Methods of statistical data analysis. Statistical analysis was performed using Microsoft Excel 2021 and MedCalc v20.104 software. Quantitative data are presented as standard descriptive statistics, including mean and standard deviation (M±SD), standard error of the mean (SE), and the 95% confidence interval for the sample mean. Variables with non-normal distribution are presented as median and interquartile range, Me [Q25; Q75]. Qualitative variables are presented as proportions and frequencies (%). Treatment outcomes were assessed during the first three months after surgery.

Comparison of the two groups for quantitative variables was performed using the nonparametric Mann-Whitney U test. Differences between the study groups for qualitative variables were assessed using Pearson's chi-square test. The significance level for hypothesis testing was set at $p<0.005$. Control of the type I error rate in pairwise intergroup comparisons was performed using the Bonferroni correction.

Results. Patient characteristics are presented in *Table 1*. The participants belonged to the intermediate- and high-risk oncological groups according to the D'Amico classification. Clinical stages ranged from T1c to T3b. No significant differences were observed between the study groups. Preoperative measurements of lower limb parameters were statistically comparable between the two groups (*Table 2*).

During surgery, 120 minutes after administration of the radiopharmaceutical, accumulation of the lymphotropic tracer was detected in the fibrofatty tissue located in the region of the external iliac vessels. The median minimum and maximum signals recorded from LNs and lymphatic channels were 240.2 [IQR 45.0; 600.0] and 1135.5 arbitrary gamma probe signal units [IQR 955.75; 1530.25], respectively. The main areas of preservation of lymphatic collectors within the field of ePLND were as follows: the lateral chain of lymphatic channels and LNs located along the lateral surface of the external iliac artery, the medial chain of lymphatic collectors located along the medial surface of the external iliac artery, and the intermediate chain of lymphatic collectors located between the external iliac vessels (*Figs. 2–5*).

During surgery, 120 minutes after administration of the radiopharmaceutical, accumulation of the lymphotropic tracer was detected in the fibrofatty tissue located in the region of the external iliac vessels. The median minimum and maximum signals recorded from LNs and lymphatic channels were 240.2 [IQR 45.0; 600.0] and 1135.5 arbitrary gamma probe signal units [IQR 955.75; 1530.25], respectively. The main areas of preservation of lymphatic collectors within the field of ePLND were as follows: the lateral chain of lymphatic channels and LNs located along the lateral surface of the external iliac artery, the medial chain of lymphatic collectors located along the medial surface

Table 1

Patient characteristics

Variable	Study group (n=23)	Control group (n=27)	*P-value*
Age (years), M [± SD]	64.74 [±8.67]	66.11 [±6.98]	0.6259
BMI, kg/m^2, M [± SD]	27.86 [±4.75]	29.94 [±5.59]	0.6127
Preoperative total PSA level, ng/mL, M [± SD]	21.13 [±28.69]	18.79 [±24.97]	0.2630
Clinical stage, n (%)			
cT1	5 (21.74%)	9 (33.33%)	
cT2	4 (17.39%)	13 (48.15%)	
cT3	14 (60.87%)	5 (18.52%)	
ISUP grade, n (%)			
ISUP 1	0 (0%)	3 (11.11%)	
ISUP 2	3 (13.04%)	9 (33.33%)	
ISUP 3	0 (0%)	5 (18.52%)	
ISUP 4	10 (43.48%)	5 (18.52%)	
ISUP 5	10 (43.48%)	5 (18.52%)	
Number of positive biopsy cores (%), M [± SD]	46.91 [±28.16]	51.30 [±0.3431]	0.3431
Prostate volume on MRI, cm^3, M [± SD]	42.19 [±17.68]	44.60 [±15.74]	0.3205

Note. M, mean; SD, standard deviation; BMI, body mass index; PSA, prostate-specific antigen; n, number of patients; ISUP, International Society of Urological Pathology.

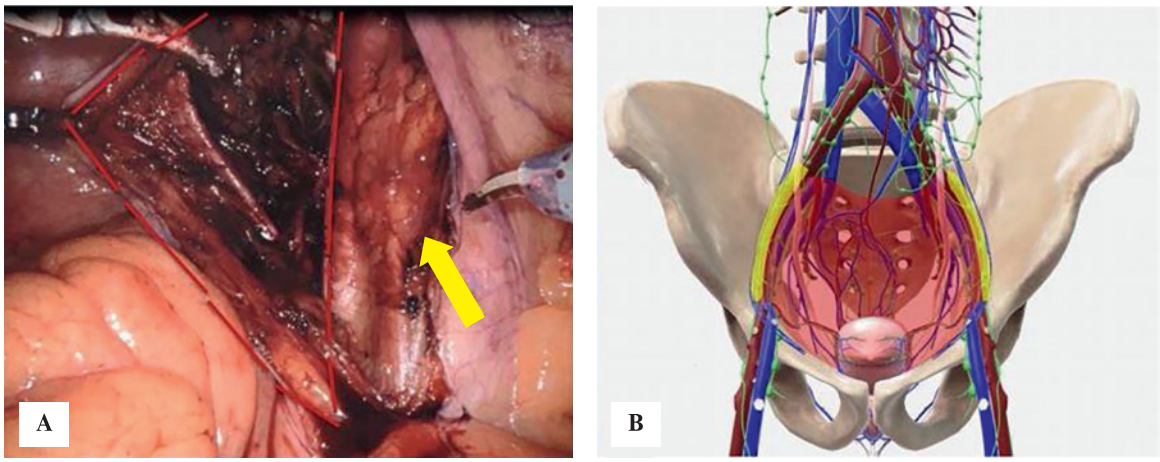

A – intraoperative view, B – schematic representation of the preserved chain. Red marking indicates the area of lymph node dissection, yellow indicates the area of preservation of lower-limb lymphatic collectors.

Fig. 2. Preservation of the lateral chain of lymphatic vessels and lymph nodes in the region of the external iliac vessels

of the external iliac artery, and the intermediate chain of lymphatic collectors located between the external iliac vessels (*Figs. 2–5*).

The operative time was significantly shorter in the study group than in the control group, averaging 106 minutes versus 115 minutes (p=0.0145). The duration of pelvic lymphadenectomy was significantly longer in the control group, averaging 27.5 minutes versus 26 minutes in the study group (p=0.038). Mean blood loss was 100 mL [IQR 100; 150] in the study group and 150 mL [IQR 100; 200] in the control group, with no significant difference (p=0.2083). The mean number of removed LNs in the study and control groups was 9.48 [±5.60] and 10.11 [±6.49], respectively (p=0.8990). According to the pathological examination, metastases in removed LNs were detected in 5 (21.74%) patients in the study group and 3 (11.11%) patients in the control group. The time to urethral catheter removal after RARP averaged 6 days in both subgroups and did not differ statistically. In the postoperative period, lymphocele developed in 2 patients in the study group and in 8 patients in the control group (Clavien-Dindo grade I), one of which required repeat laparoscopic surgery followed by drainage (Clavien-Dindo grade IIIb).

Follow-up was carried out for three months; the median total PSA level in both groups was 0.03 [IQR - 0.01; 0.08]. In addition, secondary lower limb lymphedema developed in 3 (11.1%) patients in the control group, including unilateral lymphedema in 2 patients (7.41%) and bilateral lymphedema in 1 patient (3.7%), compared with 1 patient (4.35%) in the study group. Dynamic assessment of lower limb status at 3 months after surgery demonstrated significant changes in the absolute majority of parameters in the

Table 2

Preoperative measurements of lower limb parameters

Parameter	Main group (n=23)	Control group (n=27)	P value
Circumference, Up RL 25 before surgery, cm, M [± SD]	58.09 [±5.02]	58.28 [±5.43]	0.9922
Circumference, Up LL 25 before surgery, cm, M [± SD]	57.02 [±4.91]	57.90 [±5.67]	0.6058
Circumference, Up RL 10 before surgery, cm, M [± SD]	49.92 [±4.73]	48.79 [±5.04]	0.2350
Circumference, Up LL 10 before surgery, cm, M [± SD]	49.64 [±4.33]	48.53 [±5.10]	0.2466
Circumference, Low RL 10 before surgery, cm, M [± SD]	41.17 [±2.61]	40.42 [±2.93]	0.3755
Circumference, Low LL 10 before surgery, cm, M [± SD]	40.15 [±2.80]	39.73 [±2.66]	0.7111
Circumference, Low RL 25 before surgery, cm, M [± SD]	26.25 [±1.48]	26.27 [±1.75]	0.9766
Circumference, Low LL 25 before surgery, cm, M [± SD]	26.18 [±1.44]	26.21 [±1.85]	0.9687
Upper half volume, RL before surgery, mL, M [± SD]	3513.04 [±619.41]	3461.12 [±692.88]	0.5527
Upper half volume, LL before surgery, mL, M [± SD]	3423.82 [±586.16]	3422.45 [±709.43]	0.7777
Lower half volume, RL before surgery, mL, M [± SD]	1383.10 [±152.80]	1353.27 [±178.76]	0.4895
Lower half volume, LL before surgery, mL, M [± SD]	1337.12 [±163.28]	1321.01 [±170.05]	0.7187
Total volume, RL before surgery, mL, M [± SD]	4896.13 [±757.30]	4814.39 [±842.84]	0.5658
Total volume, LL before surgery, mL, M [± SD]	4760.95 [±729.18]	4743.45 [±856.61]	0.6899

Note. Ap 25 – measurement of the circumference of the upper half of the lower limb at a distance of 25 cm above the upper edge of the patella; PNC – right lower limb; M – mean; SD – standard deviation; LNC – left lower limb; Ap 10 – measurement of the circumference of the upper half of the lower limb at a distance of 10 cm above the upper edge of the patella; Bp 10 – measurement of the circumference of the lower half of the lower limb at a distance of 10 cm below the lower edge of the patella; Bp 25 – measurement of the circumference of the lower half of the lower limb at a distance of 25 cm below the lower edge of the patella; VP – upper half; NP – lower half.

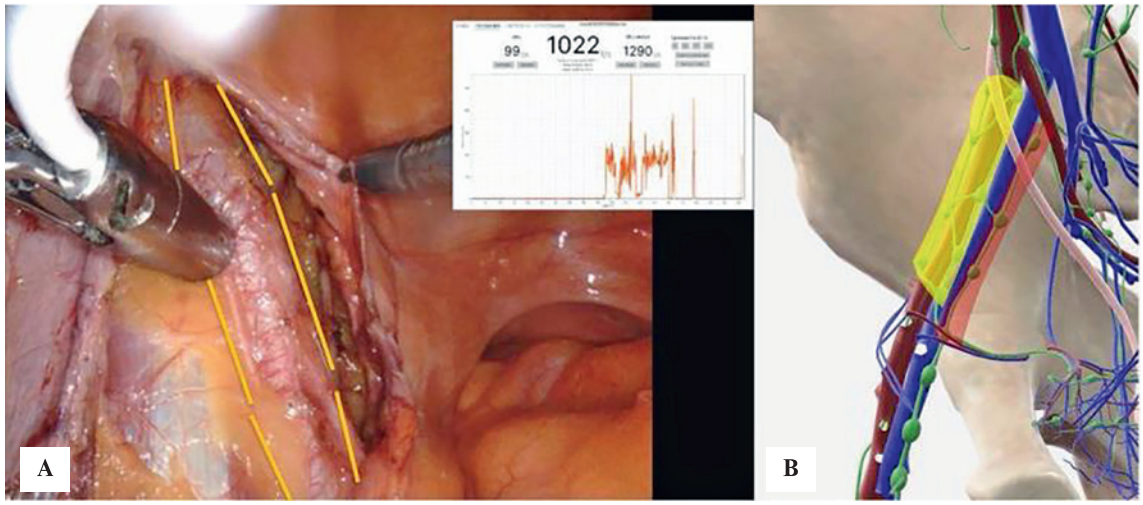

A – intraoperative view, B – schematic representation of the preserved chains. Red marking indicates the area of lymph node dissection, yellow indicates the area of preservation of lower-limb lymphatic collectors.

Fig. 3. Preservation of the lateral and medial chains of lymphatic vessels and lymph nodes in the region of the external iliac vessels

control group, further indicating the development of postoperative lower limb lymphostasis (*Table 3*).

Discussion. This is the first reported experience of intraoperative navigation using radioguided surgery and a lymphotropic tracer. According to the preliminary data, the technique may be considered a method for minimizing postoperative lymphatic complications of ePLND.

In intragroup pairwise comparisons, almost all postoperative parameters obtained from lower limb measurements differed significantly. ePLND with preservation of lower limb lymphatic collectors required less time (26.0 min [IQR 23.0; 27.0]) compared with ePLND without preservation of lower limb lymphatic collectors (27.0 min [IQR 26.0; 29.0]), which may be explained by preservation of part of the fibrofatty tissue during lymph node dissection; as a result, the surgical procedure took less time overall (106.0 min [IQR 99.0; 113.0] versus 115.0 min [IQR 109.5; 118.5]).

When analyzing the extent of PLND in the study cohort, the median number of removed LNs was 9.5 [range: 1–32]. The question of the minimum number of removed LNs required to ensure adequate control of disease progression remains controversial. In the study by Sayedin et al., the correlation between the number of LNs removed during

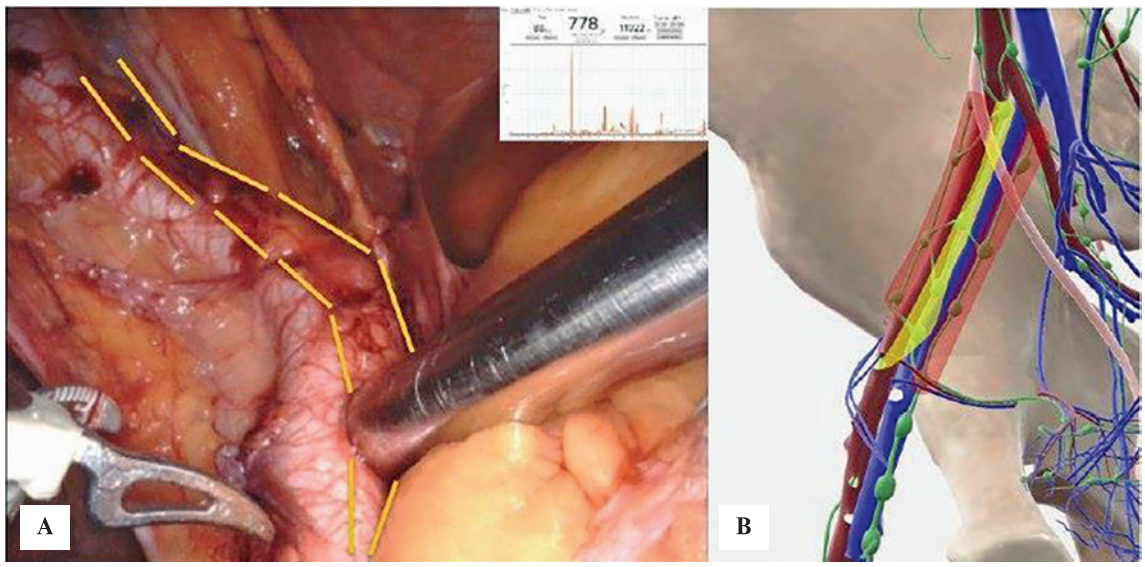

A – intraoperative view, B – schematic representation of the preserved chain. Red marking indicates the area of lymph node dissection, yellow indicates the area of preservation of lower-limb lymphatic collectors.

Fig. 4. Preservation of the medial chain of lymphatic vessels and lymph nodes in the region of the external iliac vessels

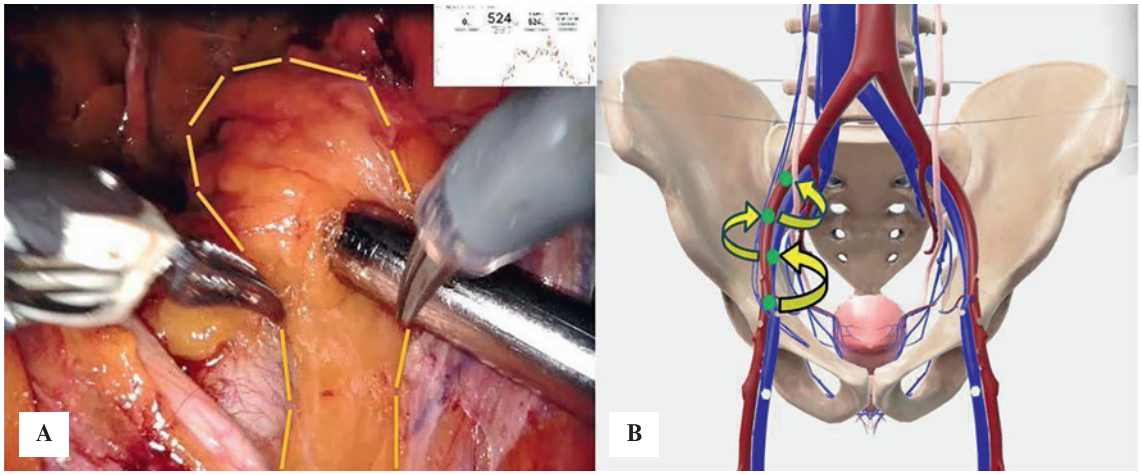

A – intraoperative view, B – schematic representation of the preserved chain. Red marking indicates the area of lymph node dissection, yellow indicates the area of preservation of lower-limb lymphatic collectors.

Fig. 5. Preservation of the intermediate chain of lymphatic vessels and lymph nodes in the region of the external iliac vessels (spiral variant)

Table 3

Postoperative outcomes at 3 months

	Variable	M [± SD] before surgery	M [± SD] at 3 months after surgery	Change (%) at 3 months	*P*-value
Study group (*n*=23)	Circumference Sup RLL 25	58.09 [±5.02]	58.16 [±5.14]	0.12	0.3083
	Circumference Sup LLL 25	57.02 [±4.91]	57.12 [±4.79]	0.18	0.2604
	Circumference Sup RLL 10	49.92 [±4.73]	50.10 [±4.84]	0.37	0.3229
	Circumference Sup LLL 10	49.64 [±4.33]	49.71 [±4.41]	0.14	0.1573
	Circumference Inf RLL 10	41.17 [±2.61]	41.16 [±2.74]	-0.03	0.2803
	Circumference Inf LLL 10	40.15 [±2.80]	40.32 [±2.86]	0.42	0.0355
	Circumference Inf RLL 25	26.25 [±1.48]	26.38 [±1.59]	0.50	0.1531
	Circumference Inf LLL 25	26.18 [±1.44]	26.27 [±1.52]	0.35	0.4342
	Volume Upper Half RLL	3513.04 [±619.41]	3530.75 [±635.44]	0.50	0.6482
	Volume Upper Half LLL	3423.82 [±586.16]	3434.40 [±584.68]	0.31	0.0885
	Volume Lower Half RLL	1383.10 [±152.80]	1387.95 [±164.06]	0.35	0.9515
	Volume Lower Half LLL	1337.12 [±163.28]	1347.98 [±168.37]	0.81	0.0186
	Volume RLL	4896.13 [±757.30]	4918.70 [±785.69]	0.46	0.6926
	Volume LLL	4760.95 [±729.18]	4782.39 [±735.96]	0.45	0.0285
Control group (*n*=27)	Circumference Sup RLL 25	58.28 [±5.43]	58.79 [±6.11]	0.87	0.0030
	Circumference Sup LLL 25	57.90 [±5.67]	58.50 [±6.42]	1.03	0.0004
	Circumference Sup RLL 10	48.79 [±5.04]	49.09 [±5.38]	0.61	0.1635
	Circumference Sup LLL 10	48.53 [±5.10]	49.20 [±6.28]	1.37	0.0027
	Circumference Inf RLL 10	40.42 [±2.93]	40.52 [±2.99]	0.24	0.1244
	Circumference Inf LLL 10	39.73 [±2.66]	40.08 [±3.00]	0.89	0.0092
	Circumference Inf RLL 25	26.27 [±1.75]	26.39 [±1.72]	0.42	0.0113
	Circumference Inf LLL 25	26.21 [±1.85]	26.33 [±1.90]	0.48	0.0093
	Volume Upper Half RLL	3461.12 [±692.88]	3519.66 [±775.87]	1.69	0.0053
	Volume Upper Half LLL	3422.45 [±709.43]	3515.70 [±867.48]	2.72	<0.0001
	Volume Lower Half RLL	1353.27 [±178.76]	1361.60 [±181.47]	0.62	0.0152
	Volume Lower Half LLL	1321.01 [±170.05]	1341.70 [±192.01]	1.57	0.0023
	Volume RLL	4814.39 [±842.84]	4881.26 [±927.74]	1.39	0.0010
	Volume LLL	4743.45 [±856.61]	4857.40 [± 038.31]	2.40	<0.0001

Note. Sup 25, circumference measurement of the upper half of the lower limb at a distance of 25 cm above the superior border of the patella; RLL, right lower limb; M, mean; SD, standard deviation; LLL, left lower limb; Sup 10, circumference measurement of the upper half of the lower limb at a distance of 10 cm above the superior border of the patella; Inf 10, circumference measurement of the lower half of the lower limb at a distance of 10 cm below the inferior border of the patella; Inf 25, circumference measurement of the lower half of the lower limb at a distance of 25 cm below the inferior border of the patella.

extended PLND and biochemical recurrence-free survival was assessed [18]. According to the results of that analysis, with a median number of removed LNs of 5 [range: 1–33], no correlation was established between the extent of lymph node dissection and recurrence-free survival in the intermediate- and high-risk patient cohorts. These conclusions are supported by a study that included a large-scale analysis of the CaPSURE database with assessment of 5-year recurrence-free survival [19]. In that cohort of 4693 patients, in which the median number of removed LNs was 5.8 [range: 0–71], no significant differences in survival were found either after stratification by risk groups or after dichotomization of the extent of PLND (<9 versus ⩾10 removed LNs). However, it should be taken into account that extending the boundaries of PLND is associated with an increased risk of postoperative complications, particularly lymphatic complications [20]. The results obtained in our study are consistent with this position.

For robot-assisted procedures, the main methods of intraoperative navigation are fluorescence guidance and radioguided surgery. Wawroschek et al. were the first to describe the potential use of ^{99m}Tc nanocolloid during PLND for the detection of lymphatic metastases. In that study, the authors noted limited sensitivity for detecting involved LNs because of variability in lymphatic drainage from the prostate [21]. In the study by Malkewicz et al., the possibilities of radioguidance in combination with single-photon emission computed tomography/computed tomography (SPECT/CT) were evaluated in patients with intermediate- and high-risk PCa who underwent radical prostatectomy with PLND. Of 119 LNs identified preoperatively, 118 were visualized using the gamma probe. Both methods had a sensitivity of 90%, whereas specificity was low at 6.06%. Despite these results, the use of the described methods makes it possible to assess individual lymphatic drainage patterns in the operative field [22].

In the article by Gondoputro et al., the efficiency and safety of a ^{99m}Tc-based prostate-specific membrane antigen tracer were evaluated for improving intraoperative navigation, with an increase in the number of detected involved LNs in 12 high-risk patients. According to the results of that study, sensitivity, specificity, positive predictive value, and negative predictive value were 76%, 69%, 50%, and 88%, respectively [23]. Combined use of intraoperative navigation methods, including radionuclide and fluorescence mapping, makes it possible to achieve a synergistic effect, increasing the probability of visualization of LNs and lymphatic channels and improving the precision of surgical technique [24, 25].

The main limitations of our study are the duration of follow-up and the small sample size. It is important to emphasize that our work is the first study to present results on the use of the lymphotropic tracer ^{99m}Tc for intraoperative preservation of lower limb lymphatic collectors in the field of PLND using a gamma probe. Further continuation of the study is planned with an increased sample size and longer follow-up to assess the dynamics of postoperative lymphatic complications. In addition, evaluation of the efficiency of a combined tracer (^{99m}Tc and indocyanine green) is planned, as well as analysis of oncological outcomes between the two study groups.

Conclusion. The use of robot-assisted radical prostatectomy and extended PLND with intraoperative navigation using a gamma probe and a lymphotropic tracer may reduce the likelihood of postoperative lymphatic complications. It should be noted that further studies are required to confirm the reliability of the obtained results.

REFERENCES

1. *Sung H, Ferlay J, Siegel RL, Laversanne M, Soerjomataram I, Jemal A, Bray F.* Global Cancer Statistics 2020: GLOBOCAN Estimates of Incidence and Mortality Worldwide for 36 Cancers in 185 Countries. CA Cancer J Clin. 2021 May;71(3):209-249. PMID: 33538338. https://doi.org/10.3322/caac.21660
2. *Lijuan Feng, Jing He, Qianjuan Chen et al.* Prostate cancer mortality time trends in BRICS, from 1990 to 2019: an age- period-cohort analysis for the Global Burden of Disease 2019, 31 October 2023. https://doi.org/10.21203/rs.3.rs-3472222/v1
3. *Попов С.В., Гусейнов Р.Г., Хижа В.В. и др.* Рак предстательной железы: современная ситуация в России и Санкт-Петербурге по данным медико-статистических показателей. Онкоурология 2023;19(1):102–14. [Popov S.V., Guseynov R.G., Khizha V.V. et al. Prostate cancer: current situation in Russia and Saint Petersburg according to medical statistical indicators. Onkourologiya Cancer Urology 2023;19(1):102–14. (In Russ.)]. https://doi.org/10.17650/1726-9776-2023-19-1-102-114
4. *Lewis-Thames MW, Langston ME, Khan S, Han Y, Fuzzell L, Xu S, Moore JX.* Racial and Ethnic Differences in Rural-Urban Trends in 5-Year Survival of Patients With Lung, Prostate, Breast, and Colorectal Cancers: 1975-2011 Surveillance, Epidemiology, and End Results (SEER). JAMA Netw Open. 2022 May 2;5(5):e2212246. PMID: 35587350. PMCID: PMC9121191. https://doi.org/10.1001/jamanetworkopen.2022.12246
5. EAU Guidelines. Edn. presented at the EAU Annual Congress Madrid 2025. ISBN 978-94-92671-29-5.
6. *Yaroslav C, Denis C, Asadulla K, Anatoliy K, Darina Y, Artem V, Leonid R, Dmitry K, Evgeniy S.* Endovideosurgical methods for treatment of local prostate cancer: Comparative functional and oncological results. Urologia. 2025 Aug;92(3):415-423. PMID: 40110858. https://doi.org/10.1177/03915603251318868
7. *Wang Y, Gieschen H, Greenberger M, Yu X, Tian G, VanderWalde N, Stockstill T, Farmer M, Rinker L, Izaguirre EW, Somer B, Ballo MT.* Survival After Robotic-assisted Prostatectomy for Localized Prostate Cancer: An Epidemiologic Study. Ann Surg. 2021 Dec 1;274(6):e507-e514. PMID: 31663972. https://doi.org/10.1097/SLA.0000000000003637
8. Клинические рекомендации. Рак предстательной железы. Ассоциация онкологов России, Общероссийская общественная организация «Российское общество онкоурологов», Общероссийская общественная организация «Российское общество клинической онкологии», Общероссийская общественная организация «Российское общество урологов». Рубрикатор клинических рекомендаций Минздрава России. 2021. ID: 12_3. Доступ: https://cr.minzdrav.gov.ru/preview-cr/12_3 (дата обращения – 28.01.2021) [Clinical guidelines. Prostate cancer. Russian Association of Oncologists. Russian Association of Oncological Urology. Russian Society of Clinical Oncology. Russian Society of Urology. Rubricator of clinical guidelines of the Ministry of Healthcare of Russia. 2021. ID: 12_3. https://cr.minzdrav.gov.ru/preview-cr/12_3 (date of access – 28.01.2021) (In Russ.)].
9. *Ding, G., Tang, G., Wang, T., Zou, Q., Cui, Y., & Wu, J.* (2024). A comparative analysis of perioperative complications and biochemical recurrence between standard and extended pelvic lymph node dissection in prostate cancer patients undergoing radical prostatectomy: a systematic review and meta-analysis. International Journal of Surgery (London, England), 110(3), 1735–1743. https://doi.org/10.1097/JS9.0000000000000997
10. *Preisser F, van den Bergh RCN, Gandaglia G, Ost P, Surcel CI, Sooriakumaran P, Montorsi F, Graefen M, van der Poel H, de la Taille A, Briganti A, Salomon L, Ploussard G, Tilki D;* EAU-YAUWP. Effect of Extended Pelvic Lymph Node Dissection on Oncologic Outcomes in Patients with D'Amico Intermediate and High Risk Prostate Cancer Treated with Radical Prostatectomy: A Multi-Institutional Study. J Urol. 2020 Feb;203(2):338-343. PMID: 31437119. https://doi.org/10.1097/JU.0000000000000504

11. *Алексеев Б.Я., Нюшко К.М., Крашенинников А.А.* и др. Хирургическое лечение больных локализованным и местнораспространенным раком предстательной железы: результаты одноцентрового исследования. РМЖ. 2017;27:2019–2025. [Alekseev B.Ya., Nyushko K.M., Krasheninnikov A.A. et al. Surgical treatment of patients with localized and locally advanced prostate cancer: the results of a single center study // RMJ. 2017. № 27. P. 2019–2025. (In Russ.)]. https://doi.org/10.17116/onkolog2018714-13
12. *Turpin A, Girard E, Baillet C, Pasquier D, Olivier J, Villers A, Puech P, Penel N.* Imaging for Metastasis in Prostate Cancer: A Review of the Literature. Front Oncol. 2020 Jan 31;10:55. PMID: 32083008. PMCID: PMC7005012. https://doi.org/10.3389/fonc.2020.00055
13. *Котов С.В., Простомолотов А.О.* Симптоматические лимфатические кисты после онкоурологических операций на органах малого таза и влияние их анатомической локализации на клиническую картину. Вестник урологии. 2020;8(4):72-79. [Kotov S.V., Prostomolotov A.O. Symptomatic lymphatic cysts after oncourological operations on the pelvic organs and influence of their anatomical localization on the clinical appearance. Urology Herald. 2020;8(4):72-79. (In Russ)]. https://doi.org/10.21886/2308-6424-2020-8-4-72-79
14. *Meershoek P, KleinJan GH, van Oosterom MN, Wit EMK, van Willigen DM, Bauwens KP, van Gennep EJ, Mottrie AM, van der Poel HG, van Leeuwen FWB.* Multispectral-Fluorescence Imaging as a Tool to Separate Healthy from Disease-Related Lymphatic Anatomy During Robot-Assisted Laparoscopy. J Nucl Med. 2018 Nov;59(11):1757-1760. PMID: 29777008. https://doi.org/10.2967/jnumed.118.211888
15. *Maurer, T., Robu, S., Schottelius, M., Schwamborn, K., Rauscher, I., van den Berg, N. S et al.* (2019). 99m Technetium-based Prostate-specific Membrane Antigen–radioguided Surgery in Recurrent Prostate Cancer. European Urology, 75(4), 659–666. https://doi.org/10.1016/j.eururo.2018.03.013
16. *Quarta L, Cannoletta D, Pellegrino F, Barletta F, Scuderi S, Mazzone E, Stabile A, Montorsi F, Gandaglia G, Briganti A.* The Role of Robot-Assisted, Imaging-Guided Surgery in Prostate Cancer Patients. Cancers (Basel). 2025 Apr 23;17(9):1401. PMID: 40361328. PMCID: PMC12070902. https://doi.org/10.3390/cancers17091401
17. *de Korne CM, Wit EM, de Jong J, Valdés Olmos RA, Buckle T, van Leeuwen FWB, van der Poel HG.* Anatomical localization of radiocolloid tracer deposition affects outcome of sentinel node procedures in prostate cancer. Eur J Nucl Med Mol Imaging. 2019 Nov;46(12):2558-2568. PMID: 31377820. https://doi.org/10.1007/s00259-019-04443-z
18. *Seyedin SN, Mitchell DL, Mott SL, Russo JK, Tracy CR, Snow AN, Parkhurst JR, Smith MC, Buatti JM, Watkins JM.* Is More Always Better? An Assessment of the Impact of Lymph Node Yield on Outcome for Clinically Localized Prostate Cancer with Low/Intermediate Risk Pathology (pT2-3a/pN0) Managed with Prostatectomy Alone. Pathol Oncol Res. 2019 Jan;25(1):209-215. PMID: 29079967. PMCID: PMC5924586. https://doi.org/10.1007/s12253-017-0349-5
19. *Berglund RK, Sadetsky N, DuChane J, Carroll PR, Klein EA.* Limited pelvic lymph node dissection at the time of radical prostatectomy does not affect 5-year failure rates for low, intermediate and high-risk prostate cancer: results from CaPSURE. J Urol. 2007 Feb;177(2):526-29; discussion 529-30. PMID: 17222625. https://doi.org/10.1016/j.juro.2006.09.053
20. *Zhang X, Zhang G, Wang J, Bi J.* Different lymph node dissection ranges during radical prostatectomy for patients with prostate cancer: a systematic review and network meta-analysis. World J Surg Oncol. 2023 Mar 6;21(1):80. PMID: 36872312. PMCID: PMC9987045. https://doi.org/10.1186/s12957-023-02932-y
21. *Wawroschek F, Vogt H, Weckermann D, Wagner T, Hamm M, Harzmann R.* Radioisotope guided pelvic lymph node dissection for prostate cancer. J Urol. 2001 Nov;166(5):1715-9. PMID: 11586208.
22. *Małkiewicz B, Bugla B, Czarnecki M, Karwacki J, Długosz P, Gurwin A, Kiełb P, Leminski A, Krajewski W, Jędrzejuk D, Bolanowski M, Hałoń A, Szydełko T.* Diagnostic Value of Radio-Guided Sentinel Node Detection in Patients with Prostate Cancer Undergoing Radical Prostatectomy with Modified-Extended Lymphadenectomy. Cancers (Basel). 2022 Oct 13;14(20):5012. PMID: 36291796. PMCID: PMC9599471. https://doi.org/10.3390/cancers14205012
23. *Gondoputro W, Scheltema MJ, Blazevski A, Doan P, Thompson JE, Amin A, Geboers B, Agrawal S, Siriwardana A, Van Leeuwen PJ, van Oosterom MN, Van Leeuwen FWB, Emmett L, Stricker PD.* Robot-Assisted Prostate-Specific Membrane Antigen-Radioguided Surgery in Primary Diagnosed Prostate Cancer. J Nucl Med. 2022 Nov;63(11):1659-1664. PMID: 35241483. PMCID: PMC9635675. https://doi.org/10.2967/jnumed.121.263743
24. *Xie D, Gu D, Lei M, Cai C, Zhong W, Qi D, Wu W, Zeng G, Liu Y.* The application of indocyanine green in guiding prostate cancer treatment. Asian J Urol. 2023 Jan;10(1):1-8. PMID: 36721695. PMCID: PMC9875158. https://doi.org/10.1016/j.ajur.2021.07.004
25. *Xu M, Li P, Wei J, Yan P, Zhang Y, Guo X, Liu C, Yang X.* Progress of fluorescence imaging in lymph node dissection surgery for prostate and bladder cancer. Front Oncol. 2024 Oct 4;14:1395284. PMID: 39429471. PMCID: PMC11486700. https://doi.org/10.3389/fonc.2024.1395284

Received 01.11.2025
Accepted 01.12.2025

Funding. The work was performed without external funding.

The contribution of the authors. All the authors have made an equal contribution to the writing of the article.

Author information:

Trishkin Maxim Dmitrievich – Ph.D. student, Institute of Urology and Human Reproductive Health of the I.M. Sechenov First Moscow State Medical University Ministry of Health of the Russian Federation (Sechenov University). Address: Bolshaya Pirogovskaya str. 2, building 1. Moscow, Russia, 119435. E-mail: maxtrishkin@bk.ru. ORCID: https://orcid.org/0009-0002-6997-2871, e-library SPIN: 7151-8271

Shpot Evgeniy Valerievich – Ph.D., MD, Professor, Deputy Director for Research, Institute of Urology and Human Reproductive Health of the I.M. Sechenov First Moscow State Medical University Ministry of Health of the Russian Federation (Sechenov University). Address: Bolshaya Pirogovskaya str. 2, building 1. Moscow, Russia, 119435. E-mail: shpot_e_v@staff.sechenov.ru. ORCID: https://orcid.org/0000-0003-1121-9430, e-library SPIN: 5025-7708, Scopus ID: 36622664600

Chernov Yaroslav Nikolaevich – Ph.D., Associate Professor, Institute of Urology and Human Reproductive Health of the I.M. Sechenov First Moscow State Medical University Ministry of Health of the Russian Federation (Sechenov University), urologist of oncologic urological department of the University clinical hospital №2 of the I.M. Sechenov First Moscow State Medical University Ministry of Health of the Russian Federation (Sechenov University). Address: Bolshaya Pirogovskaya str. 2, building 1. Moscow, Russia, 119435. E-mail: chernov_y_n@staff.sechenov.ru. ORCID: https://orcid.org/0000-0001-8425-9017, e-library SPIN: 9300-6742, Scopus ID: 57196260405

Chinenov Denis Vladimirovich – Ph.D., MD, Professor, Institute of Urology and Human Reproductive Health of the I.M. Sechenov First Moscow State Medical University Ministry of Health of the Russian Federation (Sechenov University), Head of oncologic urological department of University clinical hospital №2 of the I.M. Sechenov First Moscow State Medical University Ministry of Health of the Russian Federation (Sechenov University). Address: Bolshaya Pirogovskaya str. 2, building 1. Moscow, Russia, 119435. E-mail: chinenov_d_v@staff.sechenov.ru. ORCID: https://orcid.org/0000-0002-4275-9264, e-library SPIN: 2176-9563, Scopus ID: 24780533500

Votyakov Artem Yuryevich – urologist of the University clinical hospital №2 of the I.M. Sechenov First Moscow State Medical University Ministry of Health of the Russian Federation (Sechenov University). Address: Bolshaya Pirogovskaya str. 2, building 1. Moscow, Russia, 119435. E-mail: votyakof_a_u@gmail.com. ORCID: https://orcid.org/0000-0001-6767-3224, e-library SPIN: 6845-6948, Scopus ID: 57279162000

Hizriev Hizri Abdulaevich – resident, Institute of Urology and Human Reproductive Health of the I.M. Sechenov First Moscow State Medical University Ministry of Health of the Russian Federation (Sechenov University). Address: Bolshaya Pirogovskaya str. 2, building 1. Moscow, Russia, 119435. E-mail: hizrih@mail.ru. ORCID: https://orcid.org/0009-0004-8517-6976

Astakhova Xenia Alekseevna – student, Institute for Clinical Medicine named after N.V. Sklifosovsky of I.M. Sechenov First Moscow State Medical University of the Ministry of Health of Russia (Sechenov University). Address: 119021, Moscow, Rossolimo st., 11, building 2. E-mail: kastahova666@gmail.com. ORCID: https://orcid.org/0009-0009-4244-8747

Kurepta Irina Nikolaevna – student, Institute for Clinical Medicine named after N.V. Sklifosovsky of I.M. Sechenov First Moscow State Medical University of the Ministry of Health of Russia (Sechenov University). Address: 119021, Moscow, Rossolimo st., 11, building 2. E-mail: irrinnyska@gmail.com. ORCID: https://orcid.org/0009-0001-9925-9447

Smirnova Elena Aleksandrovna – student, Institute for Clinical Medicine named after N.V. Sklifosovsky of I.M. Sechenov First Moscow State Medical University of the Ministry of Health of Russia (Sechenov University). Address: 119021, Moscow, Rossolimo st., 11, building 2. E-mail: smirlen03@gmail.com. ORCID: https://orcid.org/0009-0005-5446-8228

Smoleevskiy Alexander Georgievich – resident, Institute of Urology and Human Reproductive Health of the I.M. Sechenov First Moscow State Medical University Ministry of Health of the Russian Federation (Sechenov University). Address: Bolshaya Pirogovskaya str. 2, building 1. Moscow, Russia, 119435. E-mail: a.smoleevsky@gmail.com. ORCID: https://orcid.org/0000-0002-8771-8589

Glybochko Peter Vitalevich – Ph. D., MD., Professor, Director of Institute of Urology and Human Reproductive Health, Rector of the I.M. Sechenov First Moscow State Medical University Ministry of Health of the Russian Federation (Sechenov University), Chairman of the Council of Rectors of Medical and Pharmaceutical Universities of Russia, Chief Freelance Specialist of the Russian Ministry of Health for Medical and Pharmaceutical Education, Vice-president of the Russian Union of Rectors, Co-Chairman of the Russian-Chinese Association of Medical Universities. Address: Bolshaya Pirogovskaya str. 2, building 1. Moscow, Russia, 119435. E-mail: rector@staff.sechenov.ru. ORCID: https://orcid.org/0000-0002-5541-2251, Scopus ID: 26435273000