©TEAM OF AUTHORS, 2026

R.U. Mammaev[1, 2], R.I. Safiullin[1], T.V. Shatylko[1], S.I. Gamidov[1, 2], I.M. Rodin[3], V.D. Myagkova[4], A.Y. Popova[1]

CONTINENCE RECOVERY AFTER ROBOTIC-ASSISTED RADICAL RETZIUS-SPARING PROSTATECTOMY

[1]National Medical Research Center for Obstetrics, Gynecology, and Perinatology named after V.I. Kulakov of the Ministry of Health of the Russian Federation, Moscow, Russia; [2]I.M. Sechenov First Moscow State Medical University (Sechenov University), Moscow, Russia; [3]Russian Biotechnological University, Moscow, Russia; [4]Almazov National Medical Research Center of the Ministry of Health of the Russian Federation; Saint-Petersburg, Russia

Corresponding author: R.U. Mammaev – postgrad. student of the Obstetrics, Gynecology, Perinatology and Reproductive Medicine Dept., I.M. Sechenov First Moscow State Medical University (Sechenov University) of the Ministry of Health of the Russian Federation; Urologist of the Andrology and Urology Division, FSBSI National Medical Research Center for Obstetrics, Gynecology and Perinatology named after V.I. Kulakov of the Ministry of Health of the Russian Federation; Moscow, Russia; e-mail: ramazan.mammaev@outlook.com

Objective. To assess time to urinary continence recovery after Retzius-sparing robot-assisted radical prostatectomy (RS-RARP) and to describe early perioperative and oncological outcomes.
Materials and methods. A retrospective analysis was performed of patients who underwent RS-RARP in 2022–2024. The primary endpoint was time to complete urinary continence (0 pads/day). Time-to-event analysis (continence recovery) was carried out using the Kaplan–Meier method, with cumulative event probability visualized as (1−S(t)) and 95% confidence intervals calculated.
Results. A total of 344 patients were included. On day 1 after urethral catheter removal, complete continence was observed in 90,1% of patients (0–1 pad/day in 97,3%). Complete continence rates were 92,1% at 1 month and 97,2% at 12 months. Mean time to continence recovery was 0,7 months (95% CI 0,428–0,973). Positive surgical margins were detected in 9% of cases; no biochemical recurrence was recorded during follow-up. Mean operative time was 113 min and mean blood loss was 121 mL.
Conclusions. RS-RARP provides rapid recovery of urinary continence with high early complete continence rates and acceptable perioperative and short-term oncological outcomes. Comparative studies versus standard RARP and comprehensive analyses of oncological and functional outcomes are needed to further clarify the advantages and limitations of this technique.

K e y w o r d s: *prostate cancer, robot-assisted radical prostatectomy, Retzius-sparing, urinary continence, urinary incontinence*

The authors declare that they have no conflicts of interest. For citation: Mammaev R.U., Safiullin R.I., Shatylko T.V., Gamidov S.I., Rodin I.M., Myagkova V.D., Popova A.Y. Continence recovery after robotic-assisted radical Retzius-sparing prostatectomy. Urologiia. 2026;2:122-127.
Doi: https://dx.doi.org/10.18565/urology.2026.2.122-127

Introduction. Prostate cancer is the most common malignant tumor in men [1]. Major risk factors include hormonal disorders, age, race-related characteristics, genetic predisposition, family history, and dietary factors, particularly high fat intake [2]. Management of patients with clinically localized prostate cancer is determined by risk stratification and life expectancy. Possible approaches include active surveillance, radical prostatectomy, prostate ablation, and external beam radiation therapy [3]. Laparoscopic radical prostatectomy as a treatment for clinically localized prostate cancer was first described in 1991 [4]. The method became widely adopted because of shorter hospital stay, reduced surgical trauma, lower blood loss, and reduced analgesic requirements compared with open surgery [1, 5]. Standard robot-assisted radical prostatectomy (S-RARP), first introduced by Abbou in 2000, is currently considered the gold standard of surgical treatment for prostate cancer [6]. In this technique, the prostate is approached anteriorly, with bladder mobilization, transection of the medial umbilical ligaments on both sides, urachus division, and dissection in the Retzius space.

One of the most significant complications is postoperative urinary incontinence, which substantially affects quality of life [7]. According to various studies, the rate of urinary incontinence after robot-assisted radical prostatectomy ranges from 4 to 50% at 1 month [8, 9].

Over the past decades, numerous modifications have been developed to improve functional outcomes [1]. These include the periurethral suspension stitch, bladder neck preservation, preservation of the puboprostatic and pubovesical ligaments, nerve-sparing techniques, preservation of urethral length, and anterior and posterior reconstructions aimed at preserving or restoring normal pelvic anatomy. However, the results vary significantly depending on the surgeon's experience [10].

In 2010, Galfano et al. proposed Retzius-sparing robot-assisted radical prostatectomy (RS-RARP). In this modification, dissection begins at the posterior surface of the prostate from the side of the seminal vesicles. When performed correctly, this technique preserves the endopelvic fascia, puboprostatic ligaments, dorsal venous complex, and detrusor apron, which contributes to earlier recovery of urinary continence [11]. In the original series of 200 patients, Galfano et al. demonstrated that 90% of men used 0 or 1 safety pad within 7 days after catheter removal; after 1 year, this figure reached 96% [12].

Aim. To assess the time to urinary continence recovery after RS-RARP and to describe oncological and perioperative outcomes.

Materials and methods. A retrospective analysis was performed of patients who underwent RS-RARP between 2022 and 2024.

The procedure was performed according to the technique proposed by A. Galfano with minor technical modifications: 1) the 12-mm assistant port was placed in the left rather than the right iliac region; 2) the seminal vesicles were not retracted using two separate ligatures passed through the anterior abdominal wall, but were transected after mobilization to the ampullae of the vas deferens; 3) a single suspending ligature was used for retraction of the parietal peritoneum; 4) when improved visualization was required, an additional ligature was passed through the anterior abdominal wall and placed on an appendage of the colon for cranial retraction. After surgery, the urethral catheter was removed on postoperative day 6 provided that cystography showed no signs of anastomotic leakage; subjective continence status was assessed on day 7, and the patients were discharged. In cases of anastomotic leakage, patients were discharged with the urethral catheter in place and instructed to remove it after 7 days. After discharge, telephone follow-up was maintained, and patients were contacted monthly to clarify the number of pads used, subjective urinary function, and severity of urinary incontinence. Patients were included if sufficient data were available, namely complete hospital records and the possibility of postoperative follow-up contact. Patients were excluded if complete medical information was unavailable.

The descriptive analysis included preoperative patient data: age, Gleason score, ISUP group, and total PSA level. Complications were assessed using the Clavien-Dindo classification.

Descriptive analysis was performed using means with confidence intervals for normally distributed data and medians with interquartile ranges for non-normally distributed data. Normality was assessed using the Shapiro-Wilk test. Time to continence recovery was analyzed using Kaplan-Meier survival analysis with censored data. For visualization, cumulative event probability was plotted as the function 1-S(t), reflecting the proportion of patients in whom the event, urinary continence, occurred by the corresponding time point. The event was defined as complete continence, that is, the use of 0 pads/day. Time to event was defined as the interval, in months, from surgery to continence recovery. A 95% confidence interval was also calculated for the function. Median time to continence recovery and the proportion of patients achieving continence at each time interval were assessed. Statistical analysis and graph plotting were performed using IBM SPSS Statistics v. 26.0.00.

Results. Of the 381 patients identified in the database, complete data were available for 344 (90.3%), and these patients were included in the analysis. Preoperative data are presented in *Table 1.*

On the first day after urethral catheter removal, complete continence, that is, no need for pads, was observed in 309 patients (90.1%). If continence was defined as the use of one pad, including a safety pad, continence was observed in 335 patients (97.3%) on day 1.

By the end of the first month, complete continence had been achieved in 92.1% of patients; by month 2, in 92.7% (325 patients); by month 3, in 93.3%; and by month 12, in 97.2%.

Positive surgical margins were observed in 31 patients (9%). No biochemical recurrence was detected during follow-up.

Among patients who did not recover continence, four used 1-2 pads per day, and one patient used 3 pads per day. The cumulative probability function is shown in *Figure 1.*

The mean time to continence recovery was 0.7 months (SD=0.139; 95% CI 0.428-0.973). The median time to continence recovery was 0 months. The proportion of patients who regained complete continence by month is shown in *Table 2.*

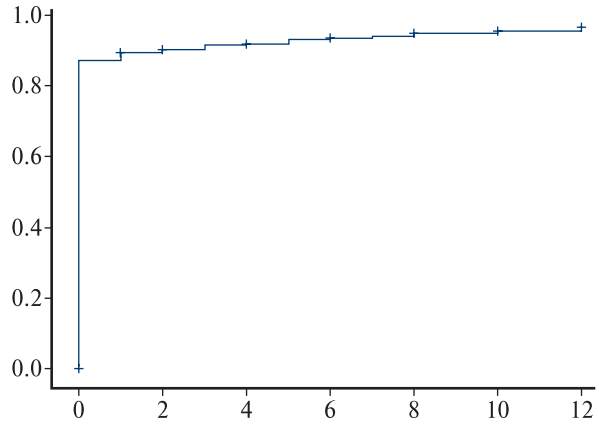

The x-axis shows the months since surgery, and the y-axis shows the proportion of patients.

Figure. Cumulative probability curve of urinary continence recovery

The mean operative time was 113 minutes (95% CI ±33 minutes), and the mean blood loss was 121 mL (95% CI ±23 mL). The rate of anastomotic leakage with urinary extravasation on cystography was 1.16% (3 patients). No Clavien-Dindo grade III complications were recorded in the early postoperative period. During the entire follow-up period, no patient developed bladder neck stenosis.

Discussion. In our study, urinary continence recovery occurred rapidly during the first month, reaching a plateau and 97.2% continence by month 12. The literature remains contradictory regarding the long-term advantage of this technique over the standard approach in terms of continence. A recent systematic review and meta-analysis reported a significant advantage of RS-RARP [3]. In the study by Davis et al., continence at 12 months was 95.7% in the modified technique group versus 85.7% in the S-RARP group [13]. In the 2022 meta-analysis by Liu et al., based on 11 studies, continence at 12 months was 91.24% versus 83.89% after RS-RARP and S-RARP, respectively [14]. Another meta-analysis by Nunes-Silva et al. assessing salvage RS-RARP demonstrated continence recovery in 95% of patients at 12 months [15]. In the retrospective multicenter study by Galfano et al. in 2021, involving 14 surgeons from 12 countries, 90.3% of patients achieved continence within 1 year.

In reviewing the literature, we noted that the first comparative studies showed an early advantage of RS-RARP that diminished over time and became non-significant by month 12 [5]. This may

Table 1

Preoperative patient characteristics at the time of surgery

Parameter	*n=344*
Age, years	64 (62-72)
PSA level, ng/mL	7.9 (5.8 – 22.725)
Prostate volume, cc	34.2 (26.875 – 75.5)
ISUP, n (%)	
1	123 (35.7)
2	115 (33.4)
3	45 (13.1)
4	34 (9.9)
5	27 (7.8)

Table 2

Change in the proportion of patients without urinary incontinence from the time of surgery

Month	Cumulative proportion of patients without urinary incontinence	
	Estimate, %	Standard error
0	90,1	0,016
1	92.1	0.015
2	92.7	0.014
3	93.3	0.014
4	93.6	0.013
5	94.3	0.013
6	94.7	0.012
7	95.0	0.012
8	95.8	0.011
9	95.8	0.011
10	96.2	0.011
11	96.2	0.011
12	97.2	0.01

be explained by the learning curve, during which tissue handling may be less delicate than after sufficient surgical experience. The learning curve for standard radical prostatectomy is about 40 procedures, which should be taken into account when interpreting these results [16].

The main advantages of this technique are generally considered to be preservation of the anterior supporting structures, such as endopelvic fascia, puboprostatic ligaments, dorsal venous complex, and detrusor apron, which are well described in the literature and associated with urinary continence [17]. However, we identified several procedural features that may contribute to favorable outcomes but are not widely discussed in the literature.

First, in RS-RARP, access is obtained through the parietal peritoneum in the projection of the seminal vesicles. This provides much easier mobilization of the seminal vesicles than the anterior standard approach.

Second, dissection along the posterior surface facilitates control of the prostatic pedicles and neurovascular bundles, which, in our opinion, leads to reduced blood loss.

Third, dissection in the plane between the prostate and Denonvillier's fascia is performed under excellent visual control, allowing better control of the surgical margin and direction of dissection and helping avoid injury to the rectum. In addition, this dissection greatly facilitates visualization of the landmark artery and subsequent nerve sparing [18].

Fourth, improved visualization and easier dissection are achieved through traction and countertraction on the seminal vesicle stumps and ampullae of the vas deferens, and manipulation of the prostate is better than with the anterior approach.

Finally, there is a fundamental difference between standard and modified techniques in anastomosis formation. During RS-RARP, the anterior aspect is approximated first; it lies directly adjacent to the anterior structures that remain undisturbed during procedure and provide natural support for the anterior lip of the anastomosis. Posteriorly, the suture is placed under direct visual control, allowing correction if necessary. In addition, posterior reconstruction techniques proposed for RS-RARP can further reinforce the suture and prevent anastomotic leakage when in doubt, for example, the Rocco modification or Lisbon stitch [19]. After switching to RS-RARP, we observed a marked decrease in anastomotic leakage; in our study, the rate was lower, 4 patients, 1.16%, than in comparable studies of the standard technique [20]. None of our patients developed bladder neck stenosis after surgery, the main risk factors for which are anastomotic leakage with secondary healing and incorrect mucosal approximation [20]. Closure of the peritoneum at the end of the procedure also reduces the risk of peritoneal symptoms in the event of anastomotic leakage.

The first reports and meta-analyses on this technique showed a higher rate of positive surgical margins compared with the standard approach [21], which raised concerns about oncological safety. Galfano et al. reported a reduction in positive surgical margins from 22% in the first 100 patients to 9% in the next 100, underlining the importance of surgical experience [12, 2]. Most positive margins were located in the anterior part of the prostate, indicating the need for careful patient selection when considering this approach [22]. Accordingly, RS-RARP is usually not recommended for patients with predominantly anterior tumors [23].

We believe that with adequate and careful dissection, the rate of positive surgical margins in RS-RARP does not exceed that of S-RARP. In the present study, no biochemical recurrence developed during follow-up, and positive surgical margins were observed in 9% of patients. We perform dissection along the anterior surface of the prostate only after complete mobilization of the posterior and lateral surfaces, which facilitates visualization of the bladder neck. Usually, it is sufficient to begin blunt dissection to identify the plane between the prostate and the bladder, which gradually transitions to sharp dissection near the bladder neck. The transverse striations of the detrusor may be used as a landmark, but this sign may be misleading and should not be the sole factor in decision-making. In the review by Wang et al., most recent studies found no difference between RS-RARP and S-RARP in terms of positive surgical margins, complications, or biochemical recurrence [5]. Therefore, we believe there is no significant difference in positive margin rate between these techniques.

The study by Golubtsova et al. found no significant difference between RS-RARP and S-RARP in operative time or blood loss [24]. We assume that, once the technique is adequately mastered, it is not inferior to but may even surpass S-RARP, although this requires comparative studies in larger cohorts.

Despite the advantages of the technique, its limitations should also be noted, namely reduced working space, absence of typical landmarks, and inability to visualize the ureteral orifices after bladder neck transection [7]. At the same time, these limitations depend on surgical experience and become less important as experience increases. The technique may be difficult to use in

patients with large prostate volume, locally advanced tumors, anatomically narrow pelvis, previous pelvic surgery, or pelvic radiation therapy [3, 10].

The limitations of the study should be emphasized: the absence of comparison with other surgical techniques and the absence of data on postoperative erectile dysfunction. In the future, we plan to continue the analysis in a larger patient population with longer follow-up, including evaluation of pentafecta, that is, both oncological and functional outcomes, as well as comparison with the standard technique and identification of factors allowing patient stratification with respect to the preferred technique.

Conclusion. Retzius-sparing robot-assisted radical prostatectomy may be considered a procedure of choice in patients with localized prostate cancer. The technique allows excellent early functional outcomes. Further studies with evaluation of trifecta and pentafecta outcomes are needed to clarify situations in which this technique is preferable to the standard approach.

REFERENCES

1. *Rosenberg JE, Jung JH, Edgerton Z, Lee H, Lee S, Bakker CJ et al.* Retzius-sparing versus standard robot-assisted laparoscopic prostatectomy for the treatment of clinically localized prostate cancer. BJU Int 2021;128:12–20. https://doi.org/10.1111/bju.15385.
2. *Galfano A, Secco S, Dell'Oglio P, Rha K, Eden C, Fransis K et al.* Retzius-sparing robot-assisted radical prostatectomy: early learning curve experience in three continents. BJU Int 2021;127:412–7. https://doi.org/10.1111/bju.15196.
3. *Gong W, Yan J, Cui Y, Zhang D, Ma Y.* Comparison of efficacy of Retzius-sparing radical prostatectomy versus standard radical prostatectomy in the treatment of prostate cancer: a systematic review and meta-analysis. Front Oncol 2025;15. https://doi.org/10.3389/fonc.2025.1547687.
4. *Schuessler WW, Schulam PG, Clayman R V., Kavoussi LR.* Laparoscopic radical prostatectomy: Initial short-term experience. Urology 1997;50:854–7. https://doi.org/10.1016/S0090-4295(97)00543-8.
5. *Wang K, Wang L, Man J, Yang J, Zhang Y, Wang H et al.* Perioperative and functional outcomes of Retzius-sparing robot-assisted radical prostatectomy vs. conventional robot-assisted radical prostatectomy: evidence based on randomized-controlled trials. J Robot Surg 2025;19. https://doi.org/10.1007/s11701-025-02337-x.
6. *Abbou C-C, Hoznek A, Salomon L, Olsson Le, Lobontiu A, Saint F, Et Al.* Laparoscopic Radical Prostatectomy With a Remote Controlled Robot. J Urol 2001:1964–6. https://doi.org/10.1097/00005392-200106000-00027.
7. *Marimpietri FS, Tourinho-Barbosa R, Roldan-Testillano R, Batista LT, Sanchez-Salas R.* Lower urinary tract symptoms after robot-assisted radical prostatectomy: a systematic review. J Robot Surg 2026;20. https://doi.org/10.1007/s11701-025-02916-y.
8. *Xu JN, Xu ZY, Yin HM.* Comparison of Retzius-Sparing Robot-Assisted Radical Prostatectomy vs. Conventional Robot-Assisted Radical Prostatectomy: An Up-to-Date Meta-Analysis. Front Surg 2021;8. https://doi.org/10.3389/fsurg.2021.738421.
9. *Barakat B, Othman H, Gauger U, Wolff I, Hadaschik B, Rehme C.* Retzius Sparing Radical Prostatectomy Versus Robot-assisted Radical Prostatectomy: Which Technique Is More Beneficial for Prostate Cancer Patients (MASTER Study)? A Systematic Review and Meta-analysis. Eur Urol Focus 2022;8:1060–71. https://doi.org/10.1016/j.euf.2021.08.003.
10. *Clements MB, Gmelich CC, Vertosick EA, Hu JC, Sandhu JS, Scardino PT, et al.* Have urinary function outcomes after radical prostatectomy improved over the past decade? Cancer 2022;128:1066–73. https://doi.org/10.1002/cncr.33994.
11. *Myers RP.* Detrusor apron, associated vascular plexus, and avascular plane: relevance to radical retropubic prostatectomy–anatomic and surgical commentary. Urology 2002;59:472–9. https://doi.org/10.1016/S0090-4295(02)01500-5.
12. *Galfano A, Di Trapani D, Sozzi F, Strada E, Petralia G, Bramerio M* et al. Beyond the Learning Curve of the Retzius-sparing Approach for Robot-assisted Laparoscopic Radical Prostatectomy: Oncologic and Functional Results of the First 200 Patients with ⩾1 Year of Follow-up. Eur Urol 2013;64:974–80. https://doi.org/10.1016/j.eururo.2013.06.046.
13. *Sadri I, Arezki A, Zakaria AS, Couture F, Nguyen D-D, Bousmaha N, et al.* Age-stratified continence outcomes of robotic-assisted radical prostatectomy. vol. 29. 2022.
14. *Liu J, Zhang J, Yang Z, Liu Q, Zhang W, Qing Z et al.* Comparison of Retzius-sparing and conventional robot-assisted laparoscopic radical prostatectomy regarding continence and sexual function: an updated meta-analysis. Prostate Cancer Prostatic Dis 2022;25:47–54. https://doi.org/10.1038/s41391-021-00459-5.
15. *Nunes-Silva I, Hidaka AK, Glina FPA, Hayashi RM, Glina S.* Can salvage Retzius-sparing robotic-assisted radical prostatectomy improve continence outcomes? A systematic review and meta-analysis study. World J Urol 2023;41:2311–7. https://doi.org/10.1007/s00345-023-04505-w.
16. *Rapoport L.M., Bezrukov E.A., Tsarichenko D.G., Martirosyan G.A., Sukhanov R.B., Krupinov G.E., Slusarenko R.I., Morozov A.O., Avakyan S.K., Sargsyan N.A.* Teaching methods for robot-assisted radical prostatectomy. Surgery. Magazine them. N.I. Pirogov. 2019;1:89-94. https://doi.org/10.17116/surgery201901189. Russian (Рапопорт Л.М., Безруков Е.А., Цариченко Д.Г., Мартиросян Г.А., Суханов Р.Б., Крупинов Г.Е., Слусаренко Р.И., Морозов А.О., Авакян С.К., Саргсян Н.А. Методы обучения робот-ассистированной радикальной простатэктомии. Хирургия. Журнал им. Н.И. Пирогова. 2019;1:89-94. https://doi.org/10.17116/hirurgia201901189).
17. *Surgical anatomy of the prostate / R.G. Biktimirov, E.N. Bolgov, D.I. Volodin, et al.* Nizhny Novgorod: Nizhny Novgorod State Medical Academy, 2017. – 72 p. – ISBN 978-5-7032-1205-9. Russian (Хирургическая анатомия простаты / Р.Г. Биктимиров, Е.Н. Болгов, Д.И. Володин и др. Нижний Новгород: Нижегородская государственная медицинская академия, 2017. – 72 с. – ISBN 978-5-7032-1205-9).
18. *Schatloff O, Chauhan S, Sivaraman A, Kameh D, Palmer KJ, Patel VR.* Anatomic Grading of Nerve Sparing During Robot-Assisted Radical Prostatectomy. Eur Urol 2012;61:796–802. https://doi.org/10.1016/j.eururo.2011.12.048.
19. *Maes K, Alves LJ, Spena G.* Posterior reconstruction in Retzius-sparing 'zero-clip' robot-assisted radical prostatectomy: 'the Lisbon stitch.' BJU Int 2023;132:461–3. https://doi.org/10.1111/bju.16097.
20. *Kakutani S, Takeshima Y, Yamada Y, Fujimura T, Nagamoto S, Enomoto Y, et al.* Clinical significance and risk factors of urethrovesical anastomotic urinary leakage following robot-assisted radical prostatectomy: a multi-institutional study. BMC Urol 2021;21:75. https://doi.org/10.1186/s12894-021-00844-1.
21. *Jiang YL, Zheng GF, Jiang ZP, Zhen-Li, Zhou XL, Zhou J et al.* Comparison of Retzius-sparing robot-assisted laparoscopic radical prostatectomy vs standard robot-assisted radical prostatectomy: A meta-analysis. BMC Urol 2020;20. https://doi.org/10.1186/s12894-020-00685-4.
22. *Checcucci E, Veccia A, Fiori C, Amparore D, Manfredi M, Di Dio M et al.* Retzius-sparing robot-assisted radical prostatectomy vs the standard approach: a systematic review and analysis of comparative outcomes. BJU Int 2020;125:8–16. https://doi.org/10.1111/bju.14887.
23. *Lv T, Yang J, Cheng B.* Oncological and functional outcomes of Retzius-sparing vs. standard robot-assisted radical prostatectomy: evidence on randomized-controlled trials studies. J Robot Surg 2025;19. https://doi.org/10.1007/s11701-025-02335-z.
24. *Golubtsova E.N., Veliev E.I., Sokolov E.A., Paklina O.V., Knyshinsky G.V.* Clinical and morphological evaluation of the results of standard robot-assisted nerve-sparing radical prostatectomy and using the technique of preserving the space of Retzius. Urologiia. 2021;3:98–103. Russian (Голубцова Е.Н., Велиев Е.И., Соколов Е.А., Паклина О.В., Кнышинский Г.В. Клинико-морфологическая оценка результатов стандартной робот-ассистированной нервосберегающей радикальной простатэктомии и с применением техники с сохранением Ретциева пространства. Урология. 2021;3:98–103).

Received 20.02.2026
Accepted 15.03.2026

Financing: The study was not sponsored

Author contributions: R.U. Mammaev – study concept and design, manuscript writing, data analysis, statistical processing; R.I. Safiullin – study supervision, concept and design of the study, approval of the final version of the manuscript; T.V. Shatylko – scientific review, manuscript writing; S.I. Gamidov – scientific review; I.M. Rodin – data acquisition and analysis, literature review, manuscript writing; V.D. Myagkova – literature review, manuscript writing; A.Y. Popova – data acquisition.

Author information:

Mammaev Ramazan Umakhanovich – postgrad. student of the Obstetrics, Gynecology, Perinatology and Reproductive Medicine Dept., I.M. Sechenov First Moscow State Medical University (Sechenov University) of the Ministry of Health of the Russian Federation Moscow, Russia; Urologist of the Andrology and Urology Division, FSBSI National Medical Research Center for Obstetrics, Gynecology and Perinatology named after V.I. Kulakov of the Ministry of Health of the Russian Federation. Address: 117997, Moscow, st. Academician Oparina, 4. ORCID: 0000-0002-7374-7020; e-mail: ramazan.mammaev@outlook.com

Safiullin Ruslan Ilyasovich – Dr. Sc. (Med), Urologist of the Andrology and Urology Division, FSBSI National Medical Research Center for Obstetrics, Gynecology, and Perinatology named after V.I. Kulakov of the Ministry of Health of the Russian Federation. Address: 117997, Moscow, st. Academician Oparina, 4. ORCID: 0000-0002-3379-5853; e-mail: russafiullin@yandex.ru

Shatylko Taras Valerevich – Cand. Sc. (Med) Urologist of the Andrology and Urology Division, FSBSI National Medical Research Center for Obstetrics, Gynecology and Perinatology named after V.I. Kulakov of the Ministry of Health of the Russian Federation. Address: 117997, Moscow, st. Academician Oparina, 4. ORCID: 0000-0002-3902-9236; e-mail: dialectic.law@gmail.com

Gamidov Safar Israilovich – Dr. Sc. (Med), Prof. of the Obstetrics, Gynecology, Perinatology, and Reproductive Medicine Dept., I.M. Sechenov First Moscow State Medical University (Sechenov University of the Ministry of Health of the Russian Federation, Head of the Andrology and Urology Division, FSBSI National Medical Research Center for Obstetrics, Gynecology, and Perinatology named after V.I. Kulakov of the Ministry of Health of the Russian Federation. Address: 117997, Moscow, st. Academician Oparina, 4. ORCID: 0000-0002-9128-2714; e-mail: safargamidov@yandex.ru

Rodin Ilya Mikhailovich – urology resident at urology department of Russian Biotechnological University. Address: 125080, Moscow, Volokolamskoe shosse, 11. ORCID: 0009-0000-9947-8941; e-mail: iliarodin25@gmail.com

Myagkova Varvara Dmitrievna – student, Almazov National Medical Research Center of the Ministry of Health of the Russian Federation. Address: 197341, St. Petersburg, Akkuratova St., 2. ORCID: 0009-0009-0752-9306; e-mail: barbaramyagkova@gmail.com

Popova Alina Yuryevna – Ph.D., urologist in the Department of Andrology and Urology, Federal State Budgetary Scientific Institution National Medical Research Center for Obstetrics, Gynecology, and Perinatology named after V.I. Kulakov of the Ministry of Health of the Russian Federation. Address: 117997, Moscow, st. Academician Oparina, 4. RSCI AuthorID: 650291 ORCID: 0000-0003-1163-5602; e-mail: a_popova@oparina4.ru